



Česká urologická společnost ČLS JEP
Societas Urologica Bohemica
Czech Urological Society

JEUS 2022



ÚVN
ÚSTŘEDNÍ VOJENSKÁ NEMOCNICE
Vojenská fakultní nemocnice Praha

Dopplerovské vyšetření klinická část

Kamil Belej

*Urologické oddělení a Centrum robotické chirurgie
Ústřední vojenská nemocnice-Vojenská fakultní nemocnice
Praha*

Dopplerovská ultrasonografie

klinická část

- Ledviny – cévní zásobení
- Močovody – zobrazení juxtavezikální části (twinkling)
- Močový měchýř – ejakulace moče (jet)
- Prostata a semenné vajíčky - cévní zásobení
- Penis a močová trubice u mužů
- Funiculus spermaticus a obsah skrota (varle, nadvarle, přívěsky)

Dopplerovská ultrasonografie

klinická část

- Vrozené vady ledvin, močových cest a mužských pohlavních orgánů
- Zánětlivá onemocnění (difuzní, ložisková, komplikace)
- Urolitiáza (lokalizace, komplikace)
- Ložiskové změny (nádory)

Dopplerovská ultrasonografie

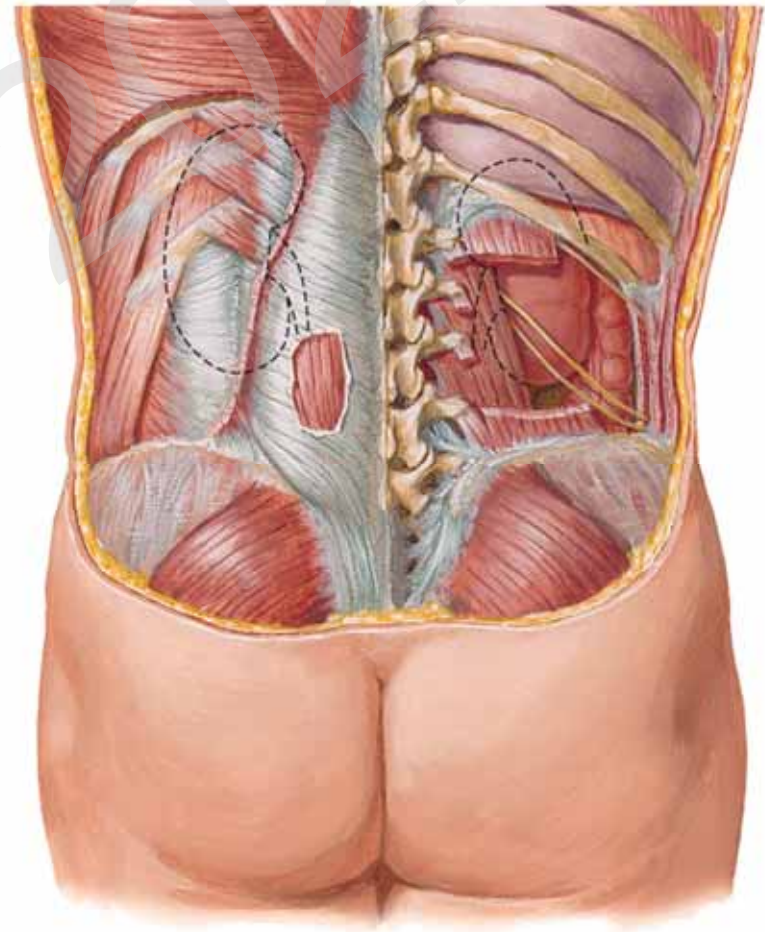
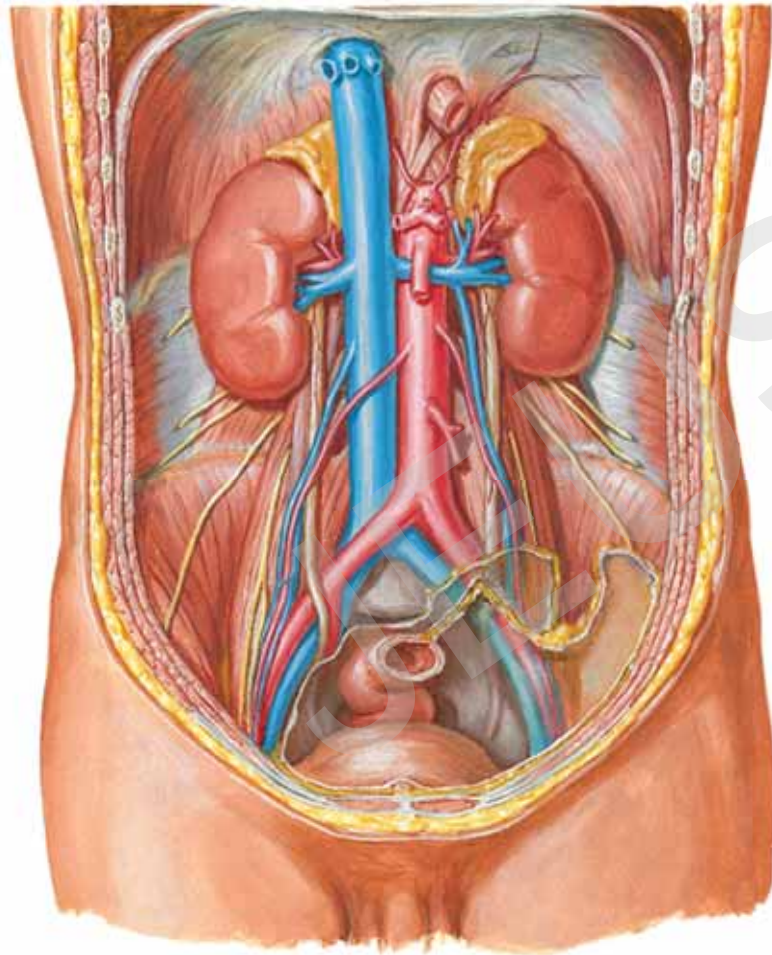
klinická část

- Funkční poruchy (neurogenní poruchy, inkontinence, píštěle)
- Andrologie (erektilní dysfunkce, infertilita)
- Akutní stavy (poruchy prokrvení, úrazy)
- Jatrogenní onemocnění
(záněty, poranění, striktury, cizí tělesa)

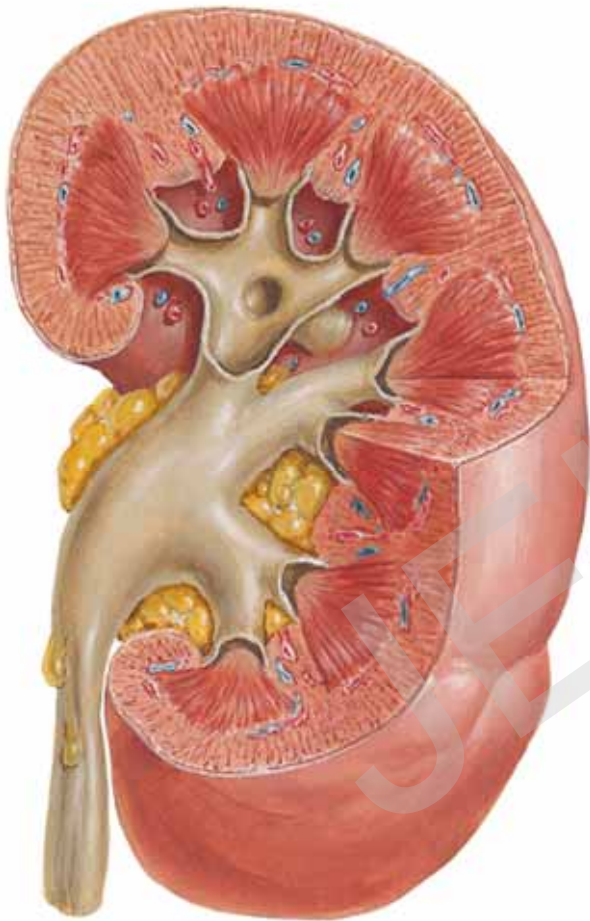
Dopplerovské vyšetření ledviny

Dopplerovská ultrasonografie

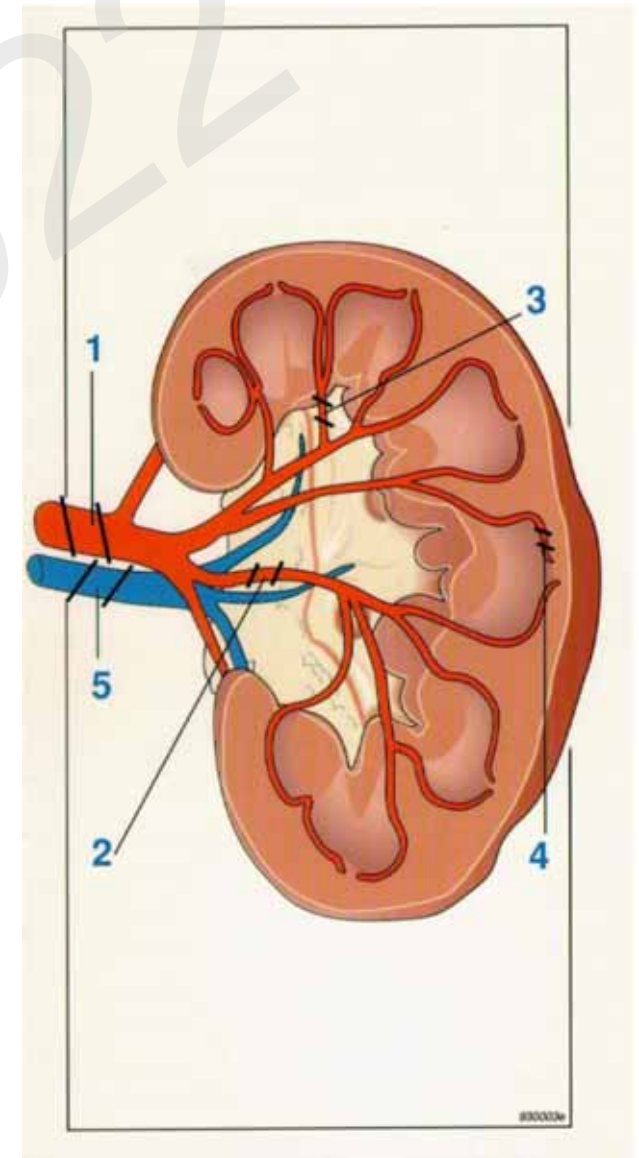
ledviny



Dopplerovská ultrasonografie *ledviny*

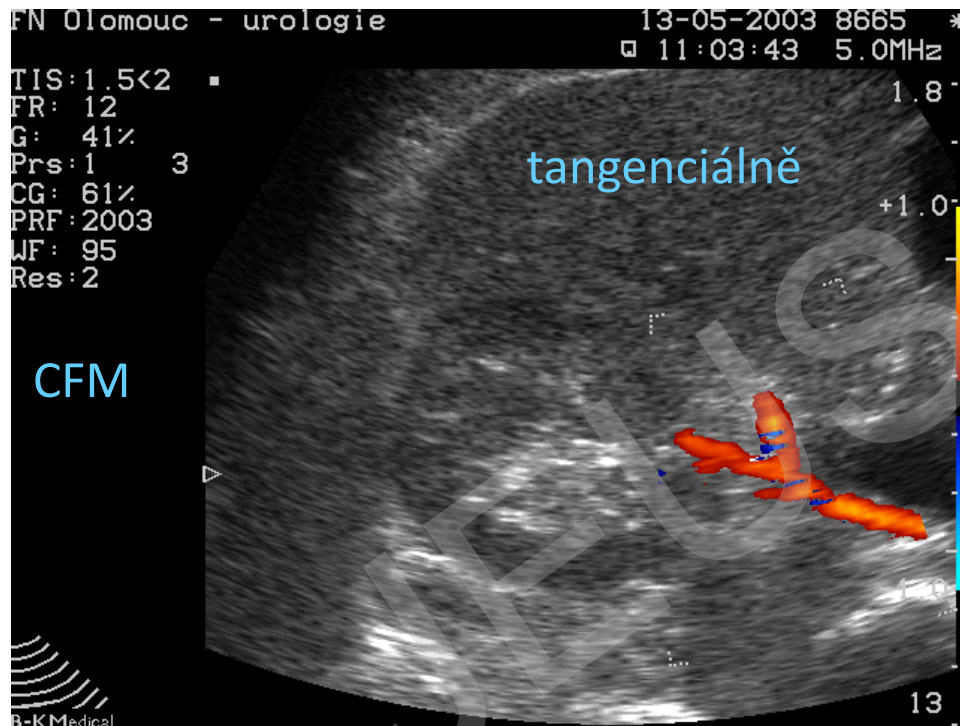


- a. renalis ①
- a. interlobaris ②
- a. interlobularis ③
- a. arcuata ④
- periferie
- v. renalis ⑤

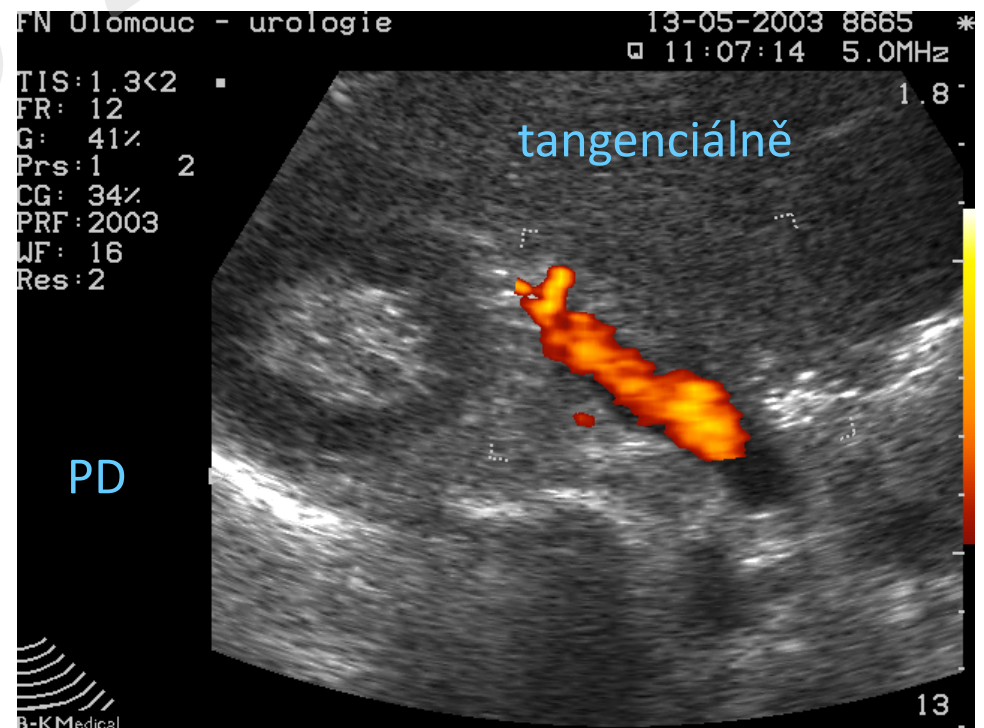


Dopplerovská ultrasonografie *ledviny*

a. renalis

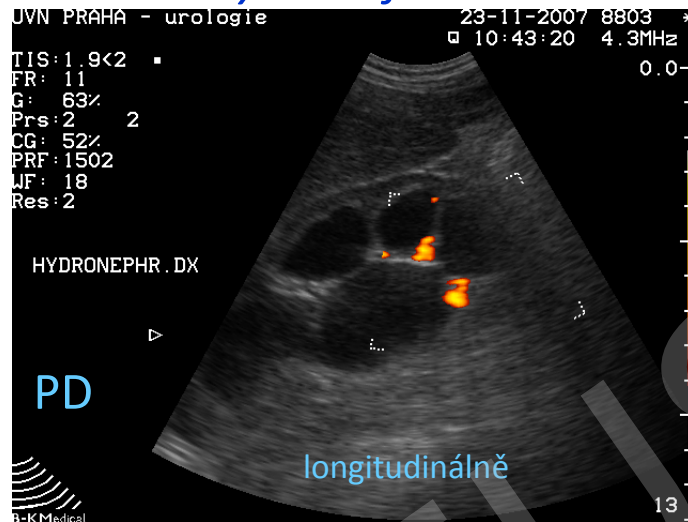


v. renalis

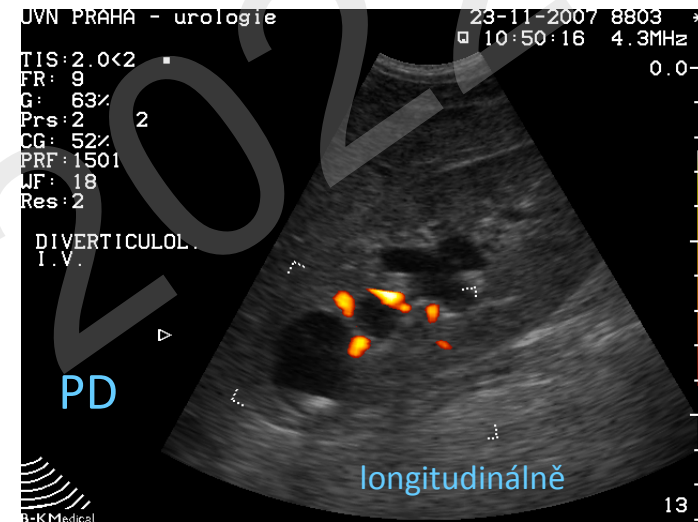


Dopplerovská ultrasonografie ledviny

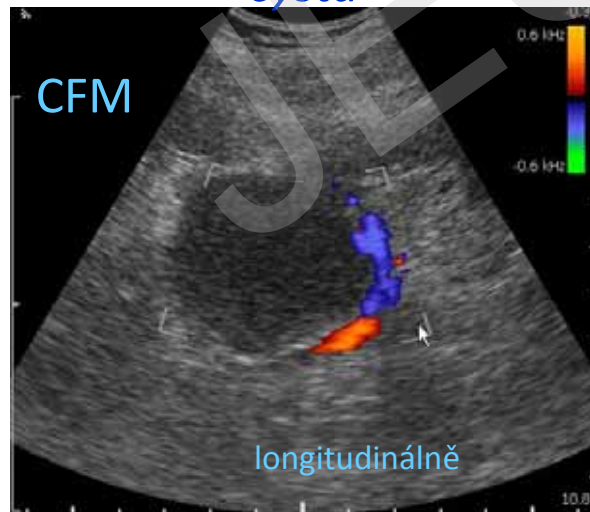
hydronefróza



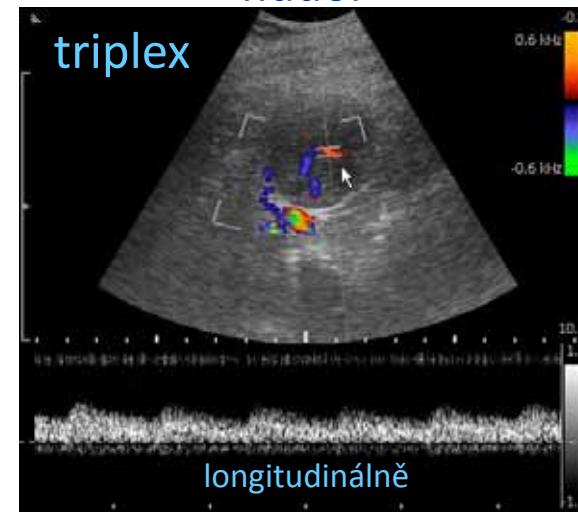
litiáza divertiklu



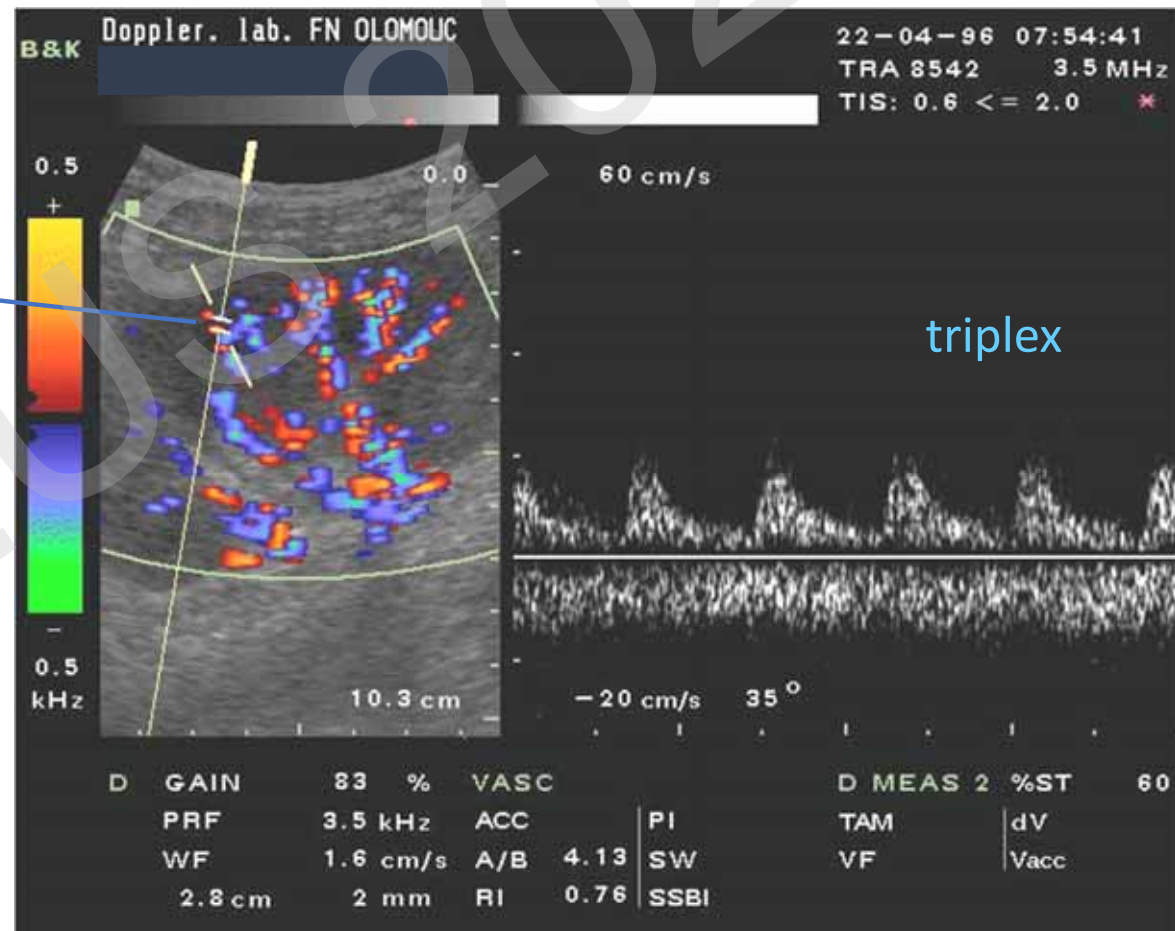
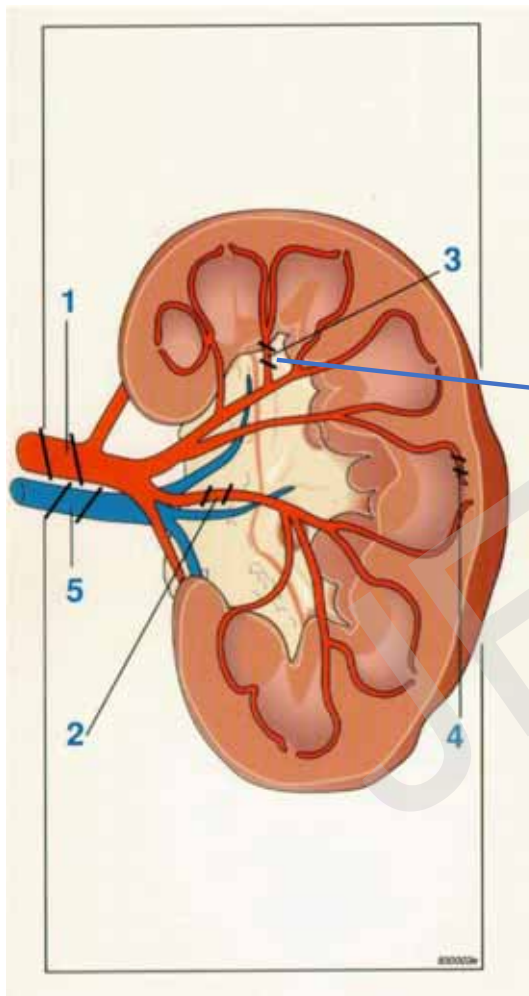
cysta



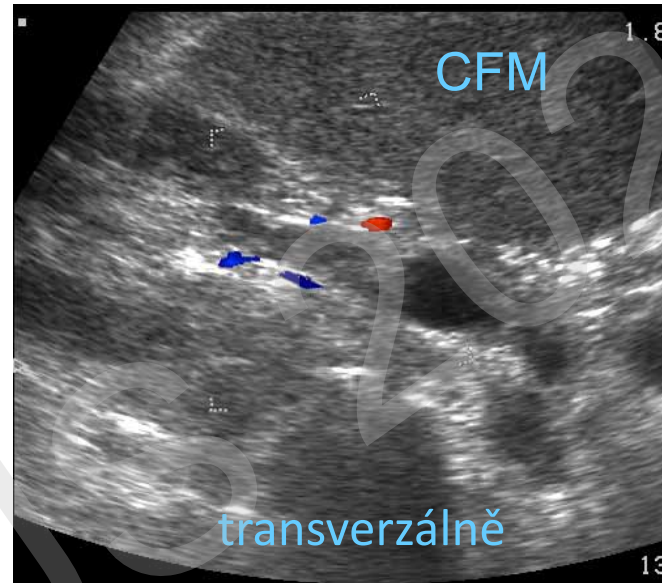
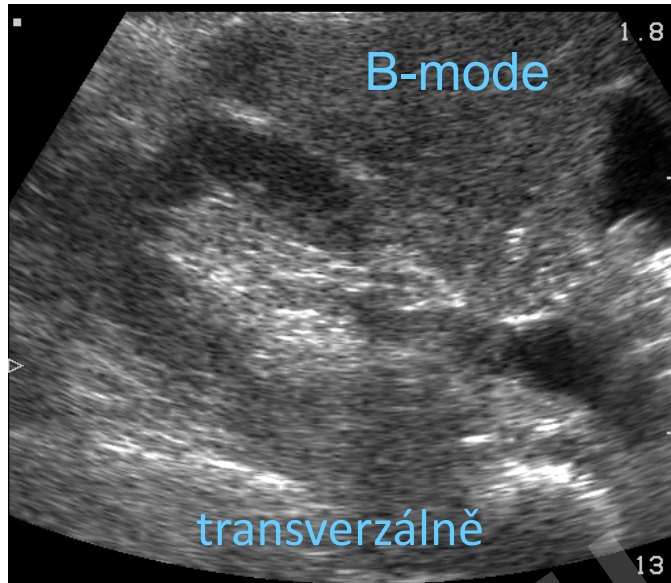
nádor



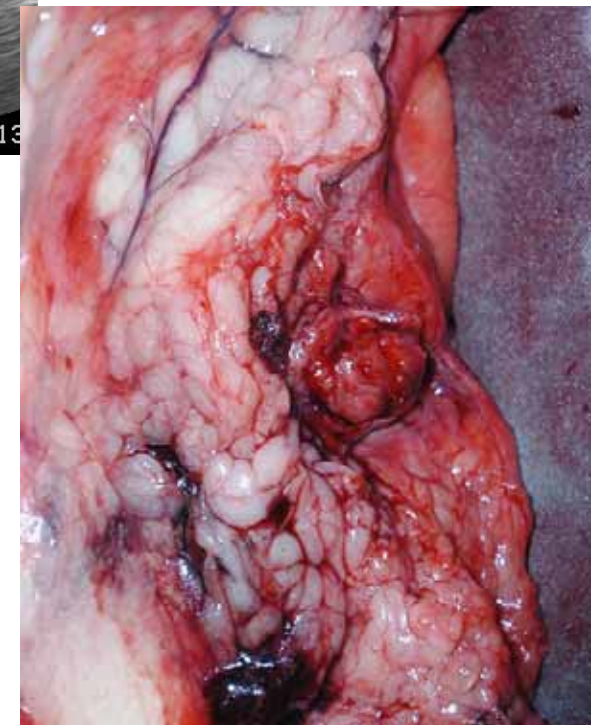
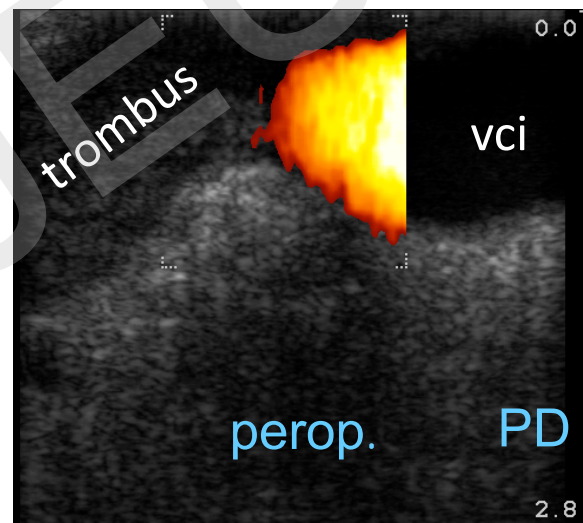
Dopplerovská ultrasonografie *ledviny*



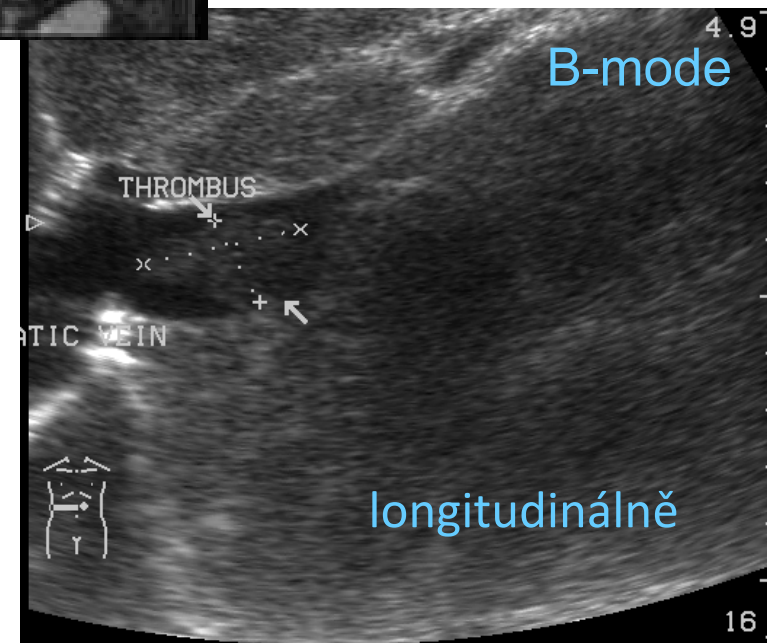
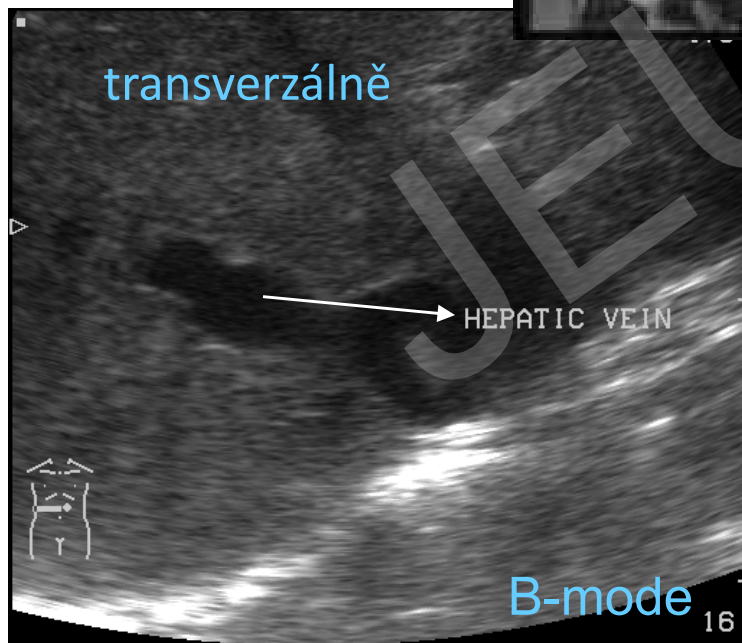
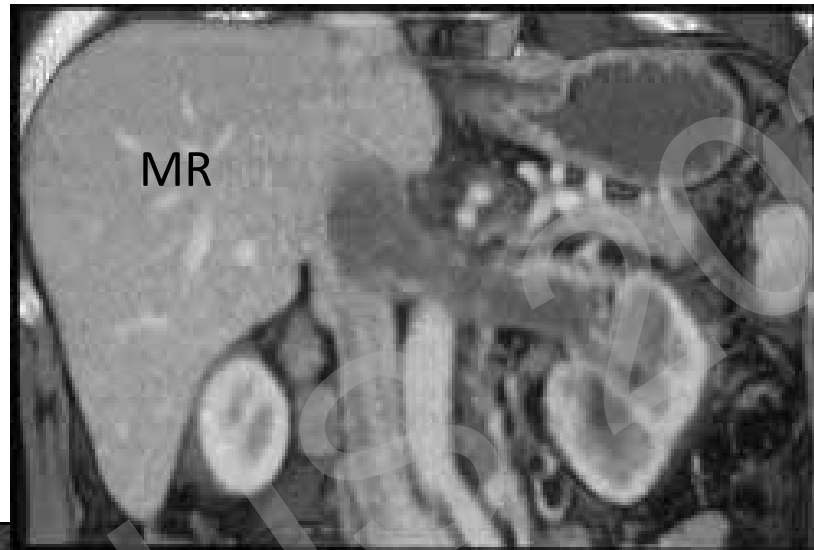Dopplerovská ultrasonografie *nádorový trombus*



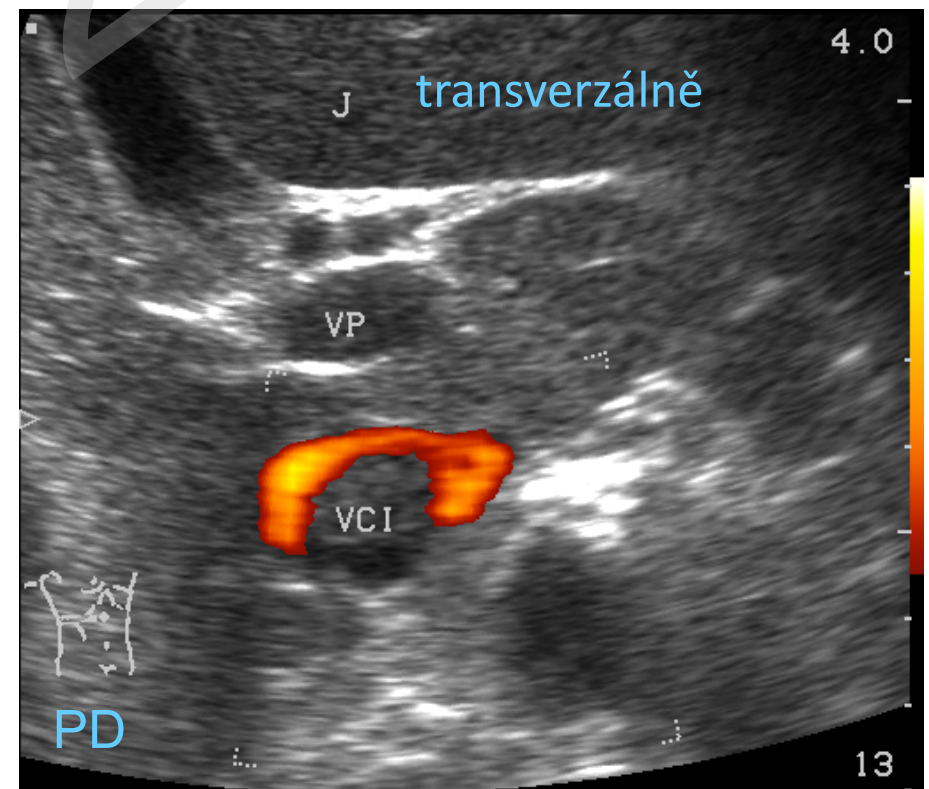
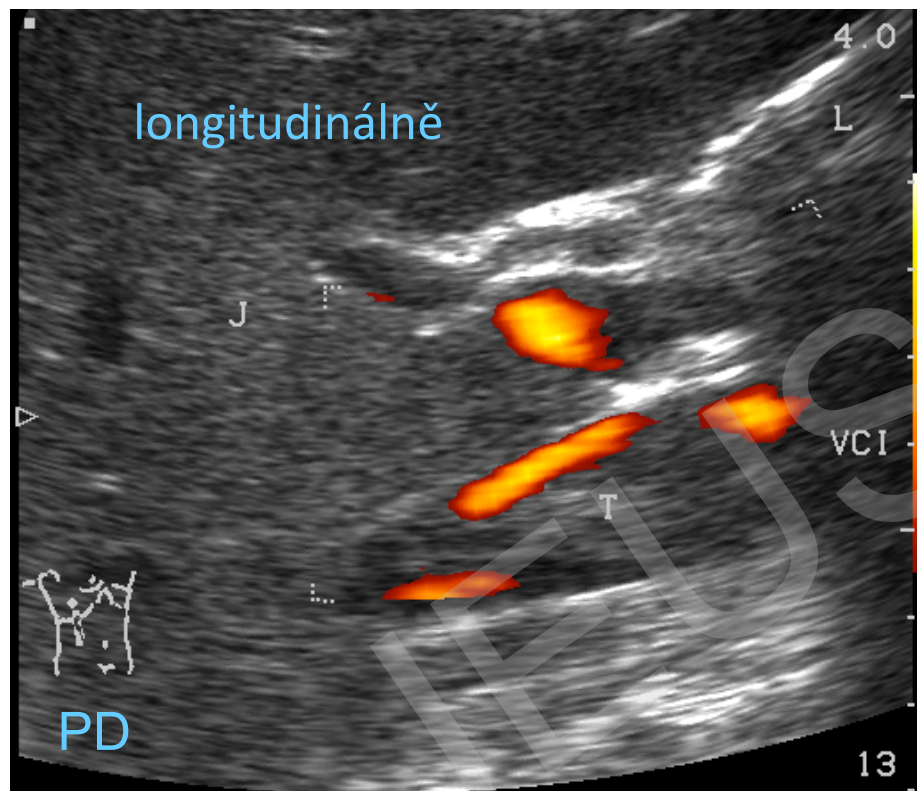
pooper.



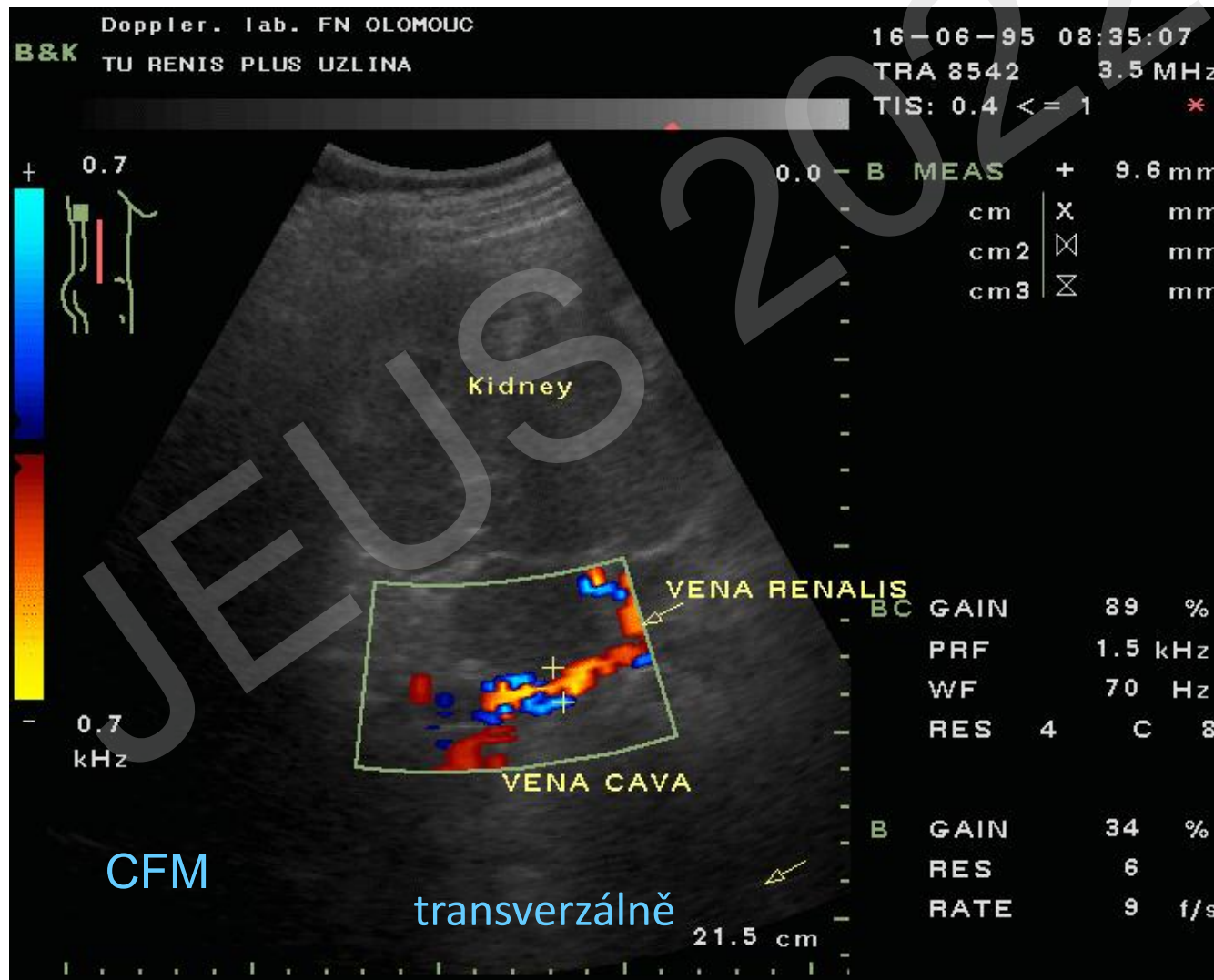
Dopplerovská ultrasonografie *nádorový trombus*



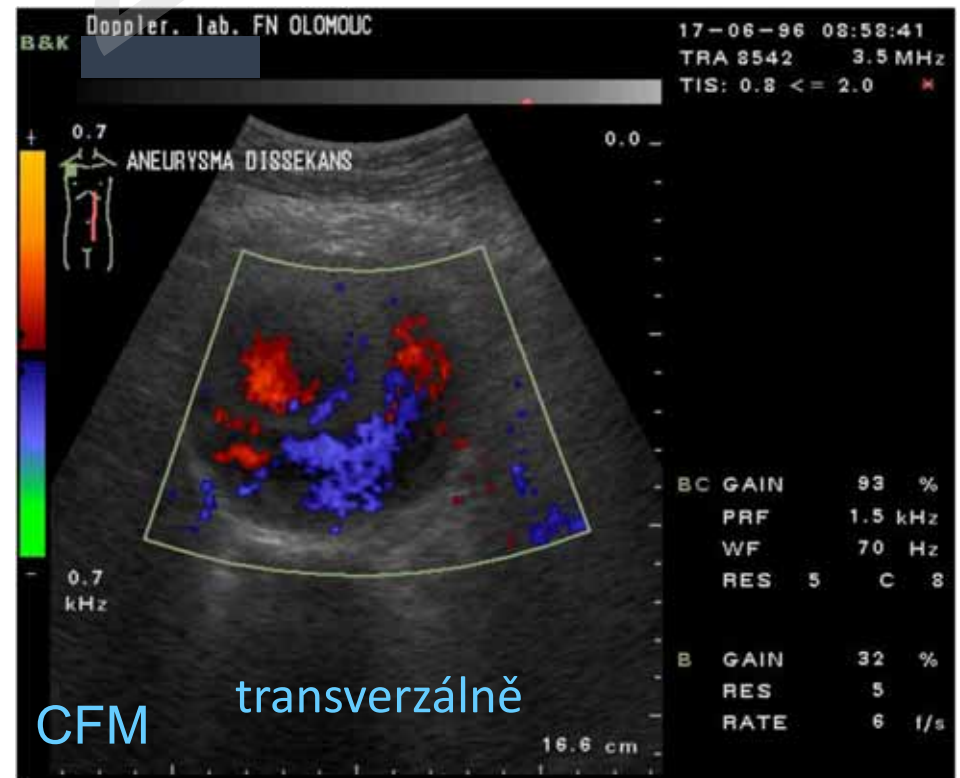
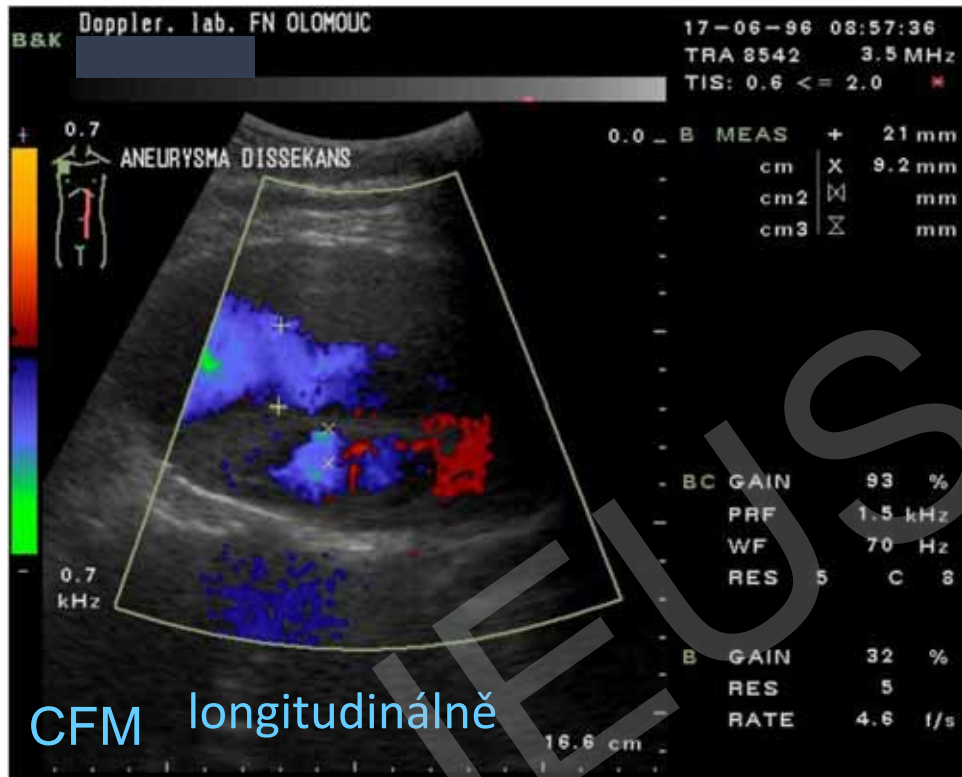
Dopplerovská ultrasonografie *nádorový trombus*



Dopplerovská ultrasonografie *nádorové postižení uzlin*



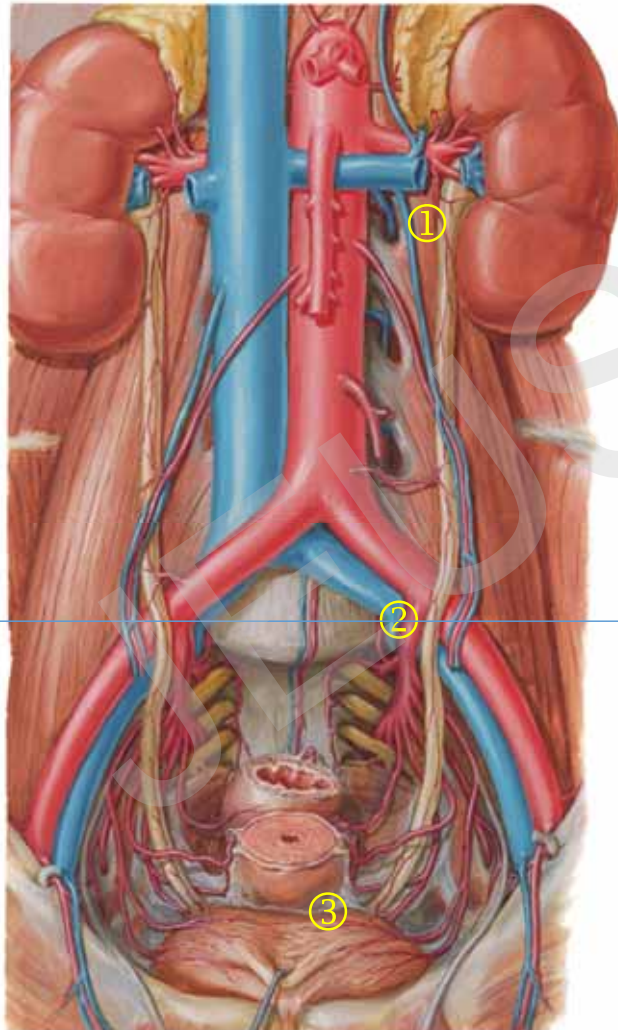
Dopplerovská ultrasonografie *aneurysma aorty*



Dopplerovské vyšetření močovody

Dopplerovská ultrasonografie *močovody*

břišní
část

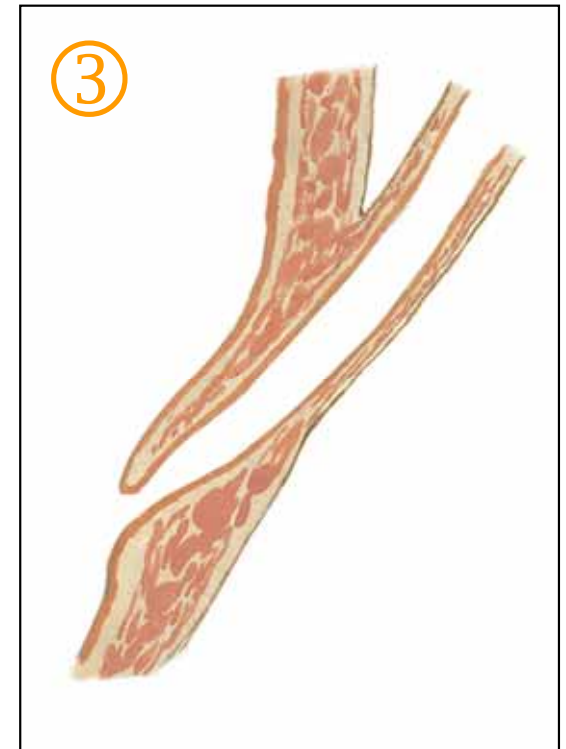


pelviureterální přechod ①

křížení s vasa iliaca ②

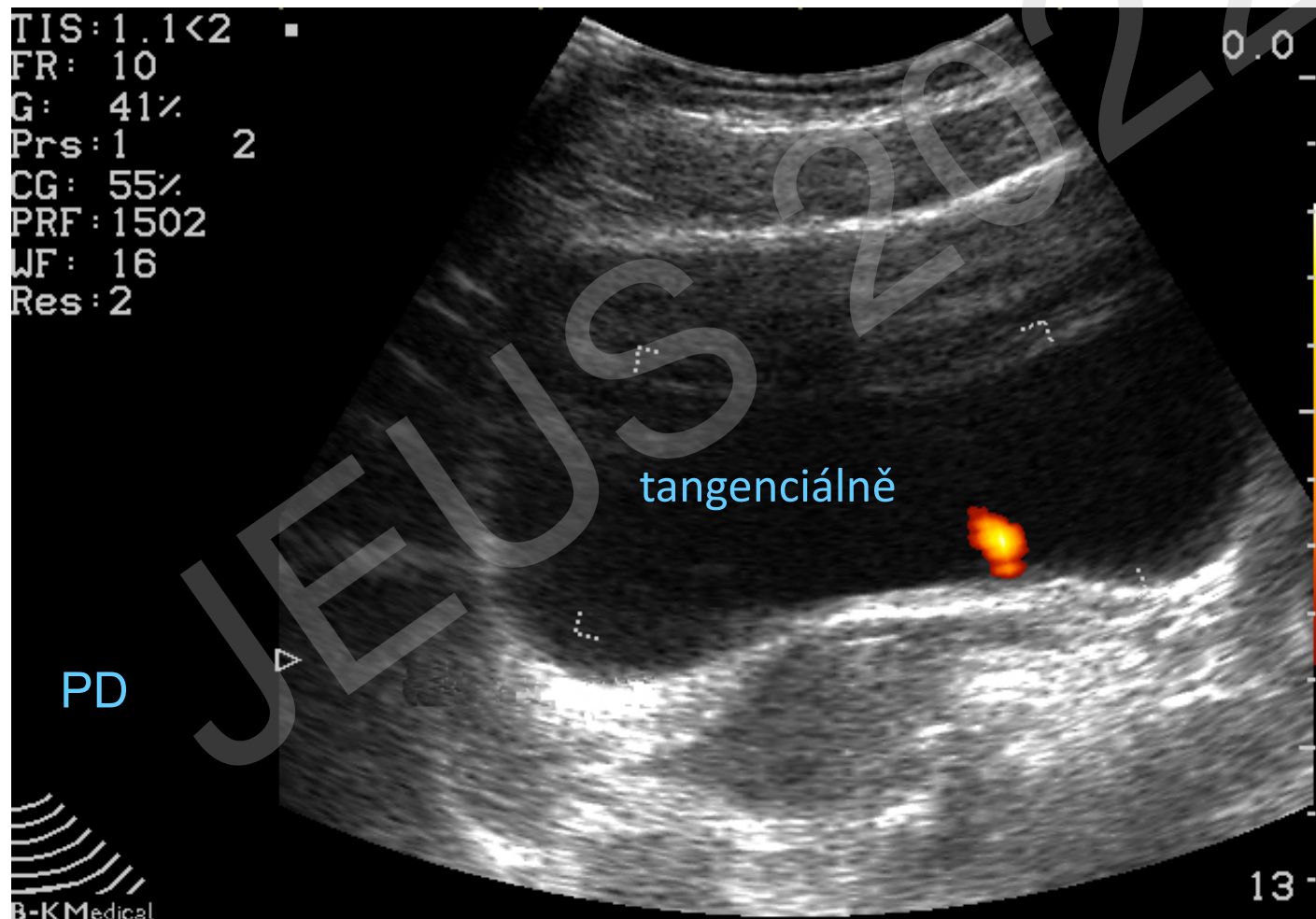
intramurální úsek ③

③

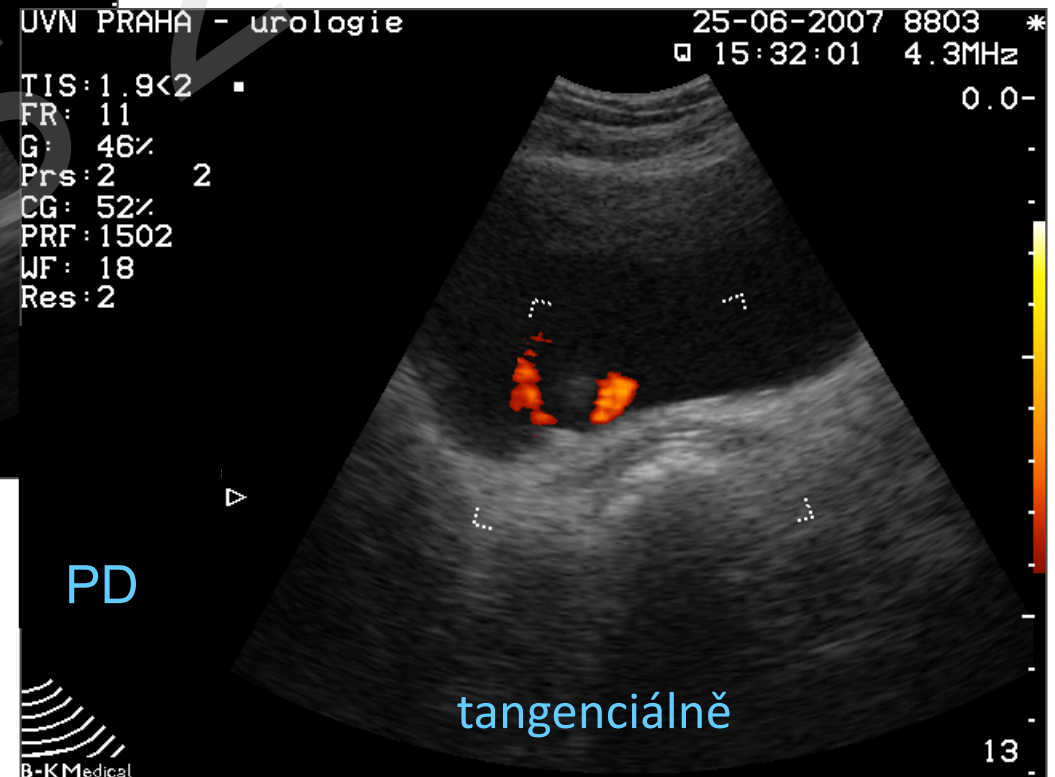
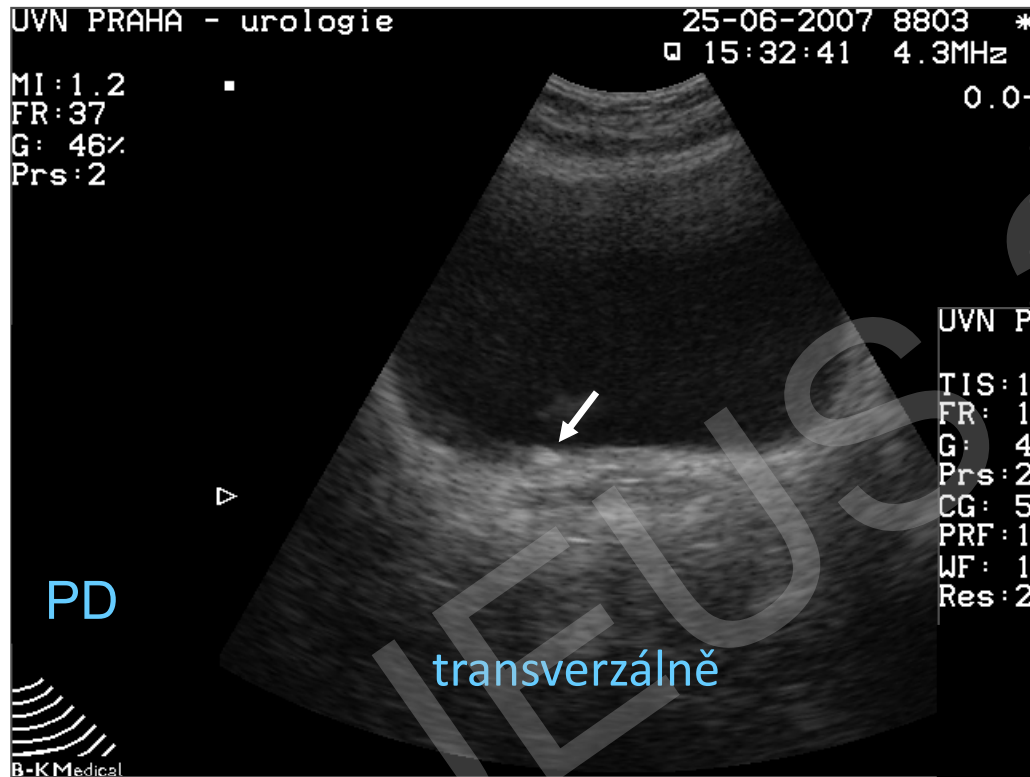


pánevní
část

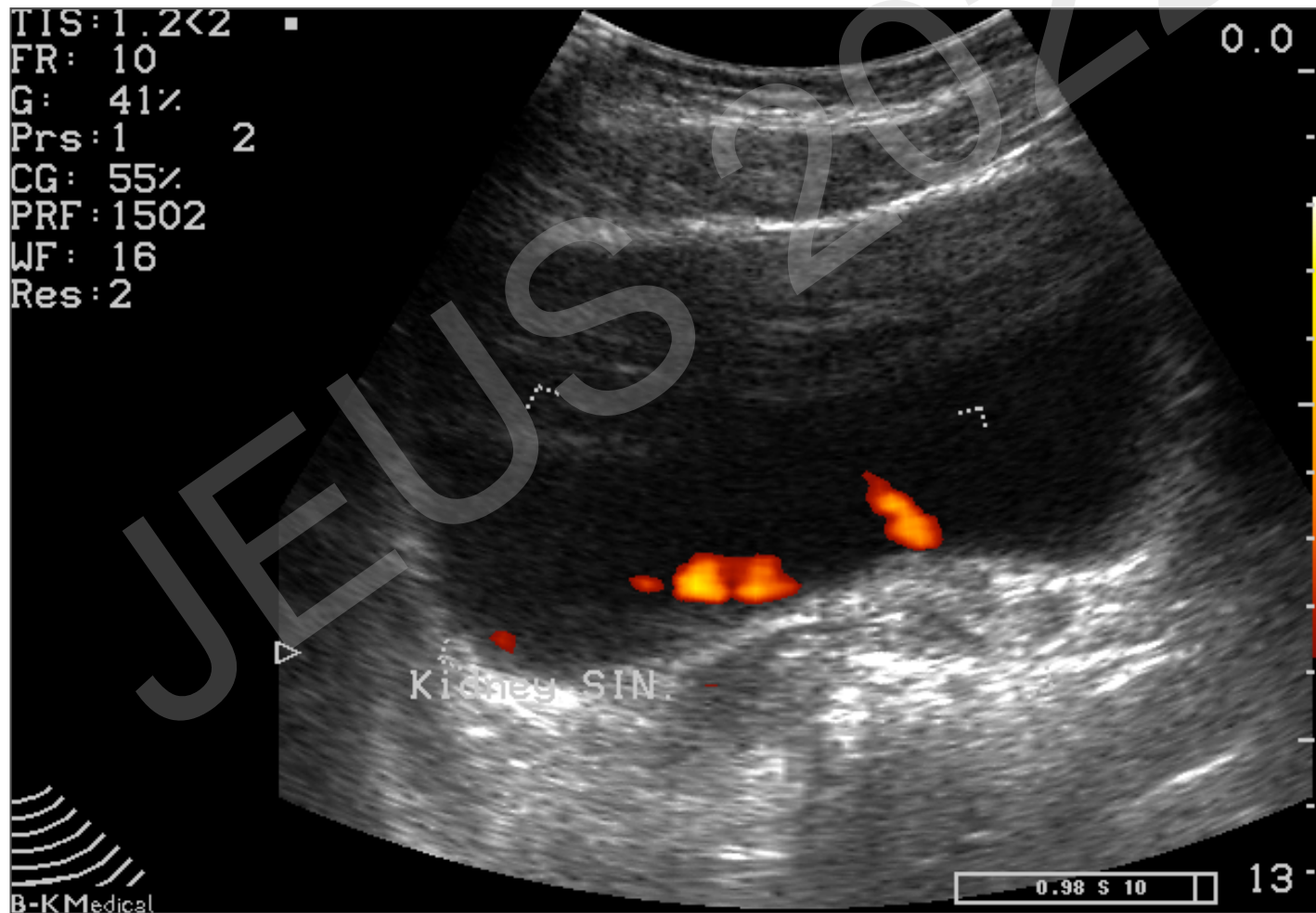
Dopplerovská ultrasonografie *ejakulace moče*



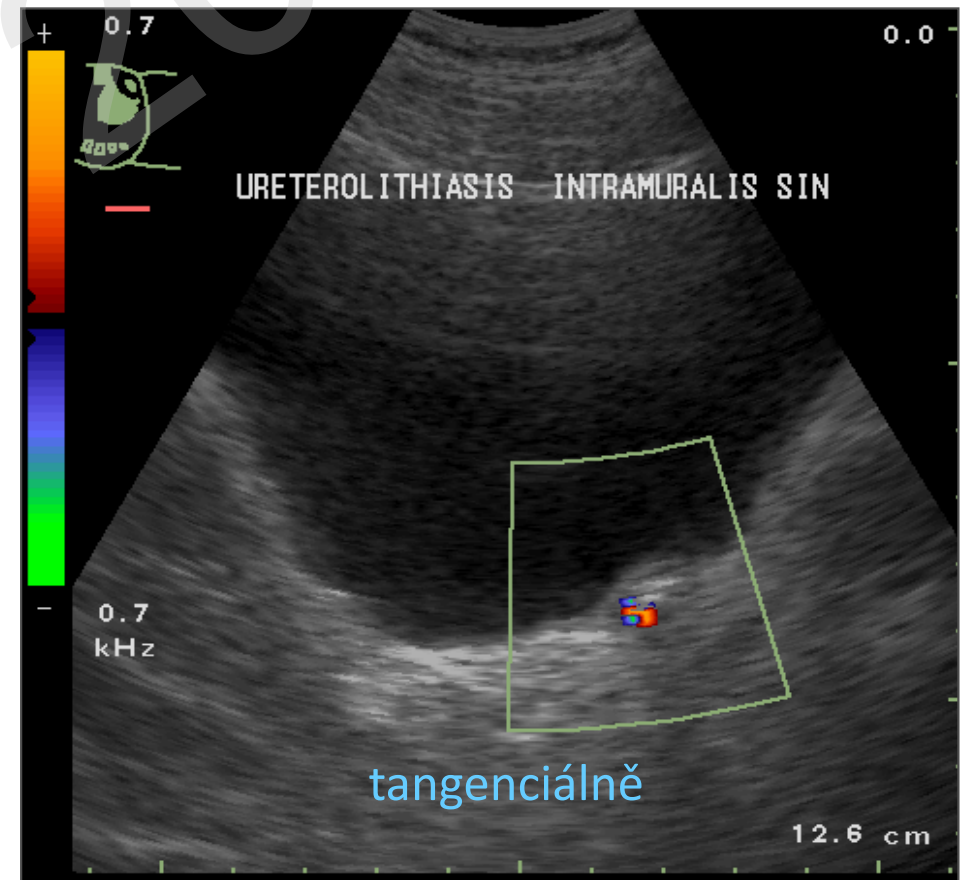
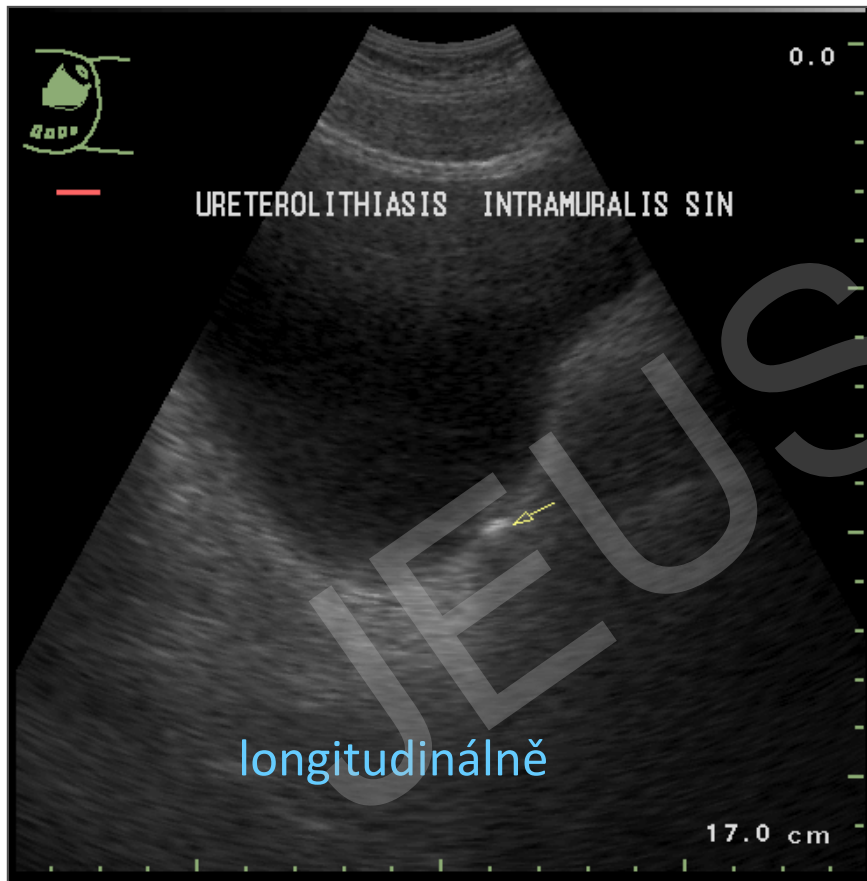
Dopplerovská ultrasonografie ejakulace moče - ureterolitiáza



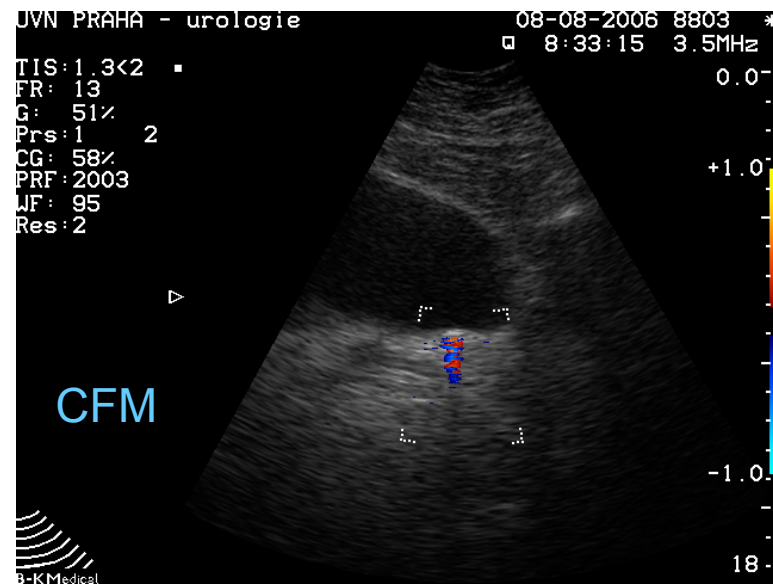
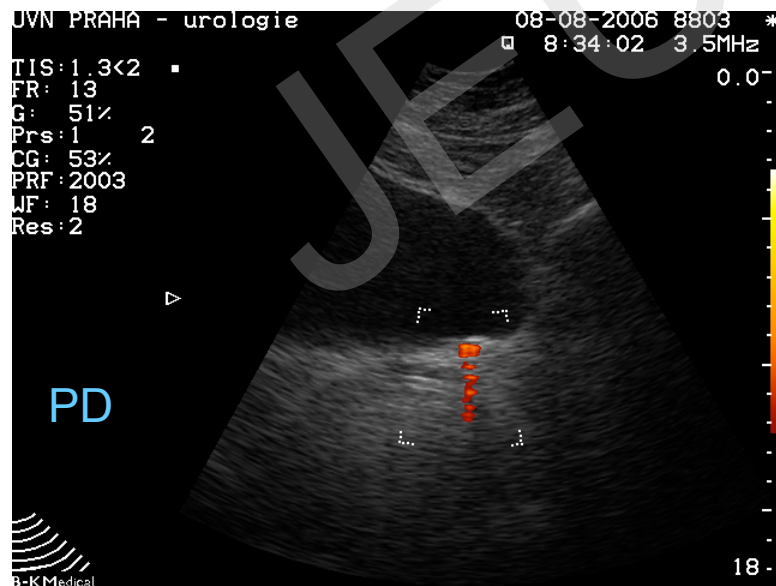
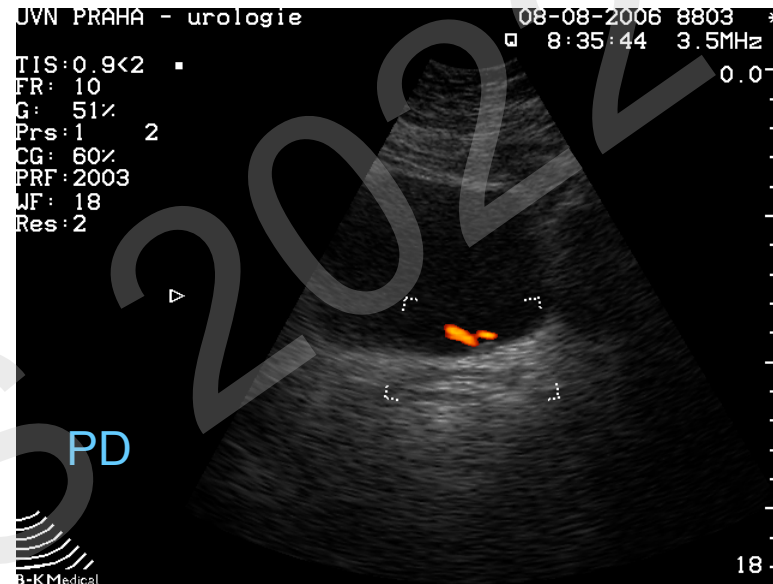
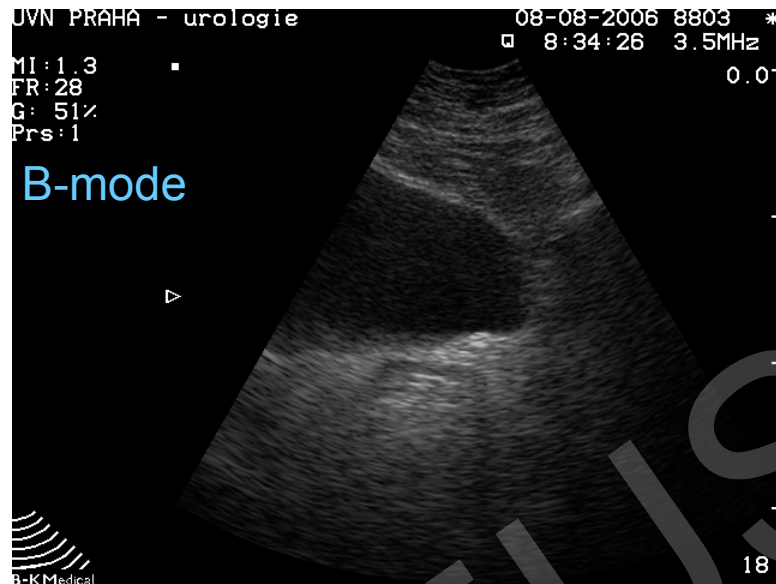
Dopplerovská ultrasonografie *ejakulace moče – zdvojení močovodů*



Dopplerovská ultrasonografie *twinkling*

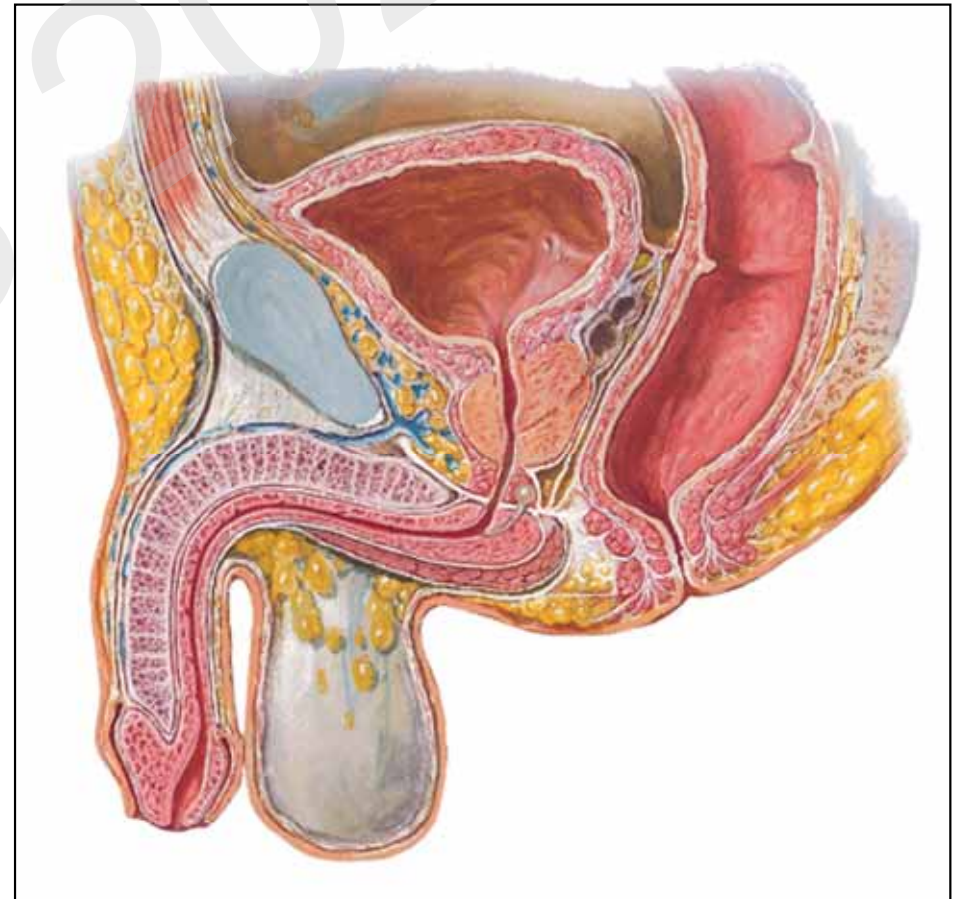
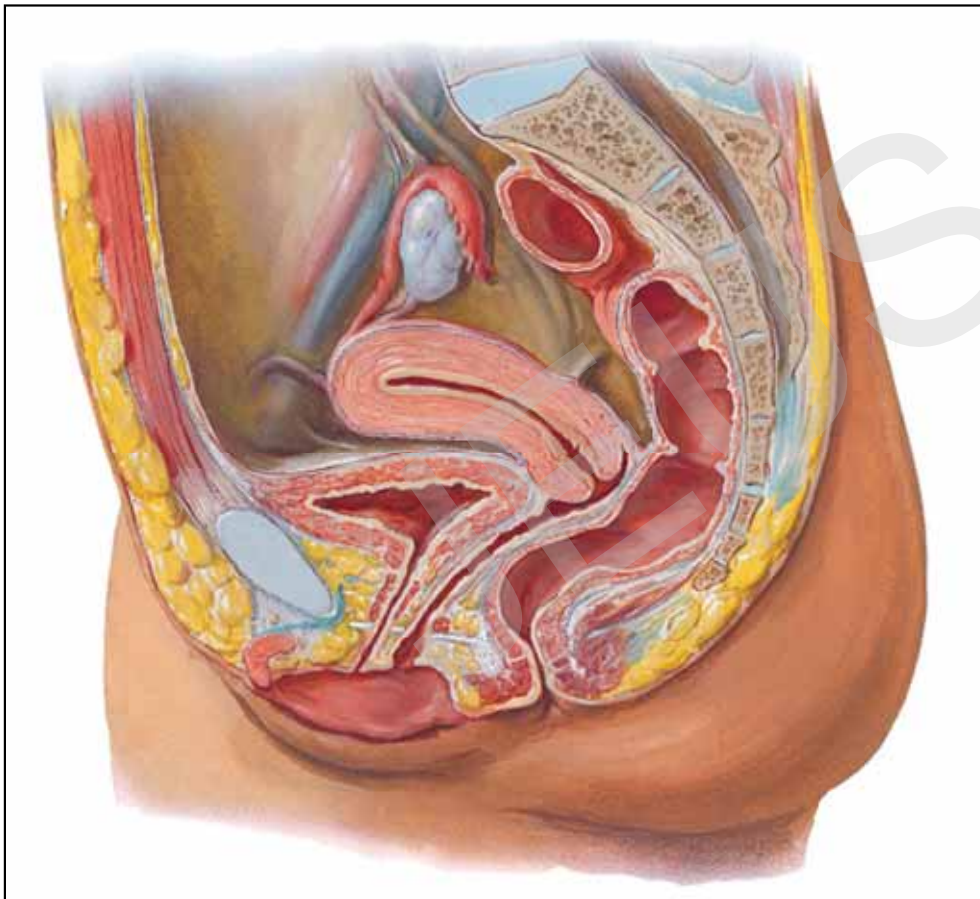


Dopplerovská ultrasonografie *ureterolitiáza – ejakulace + twinkling*



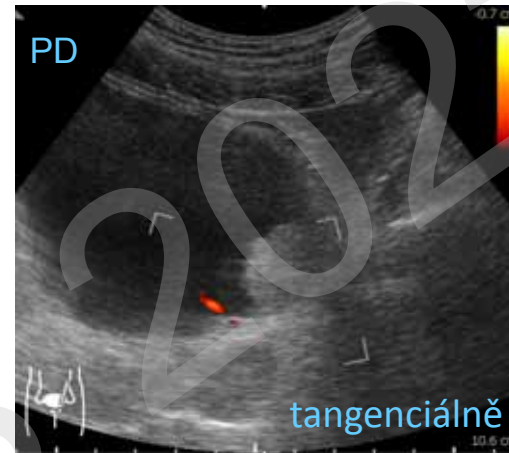
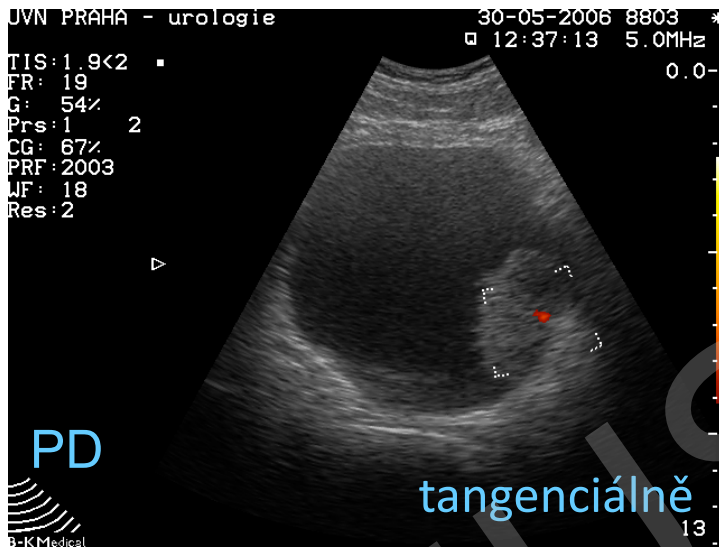
Dopplerovské vyšetření močový měchýř a prostata

Dopplerovská ultrasonografie *močový měchýř a prostata*

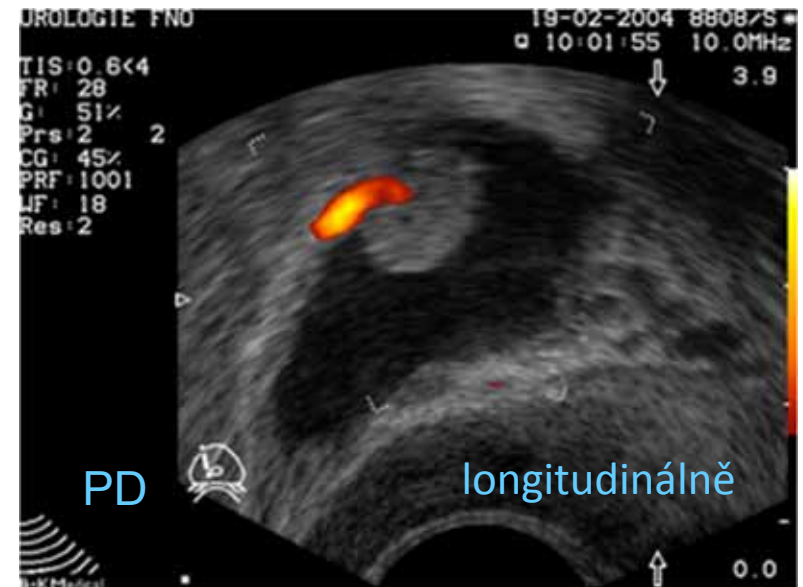
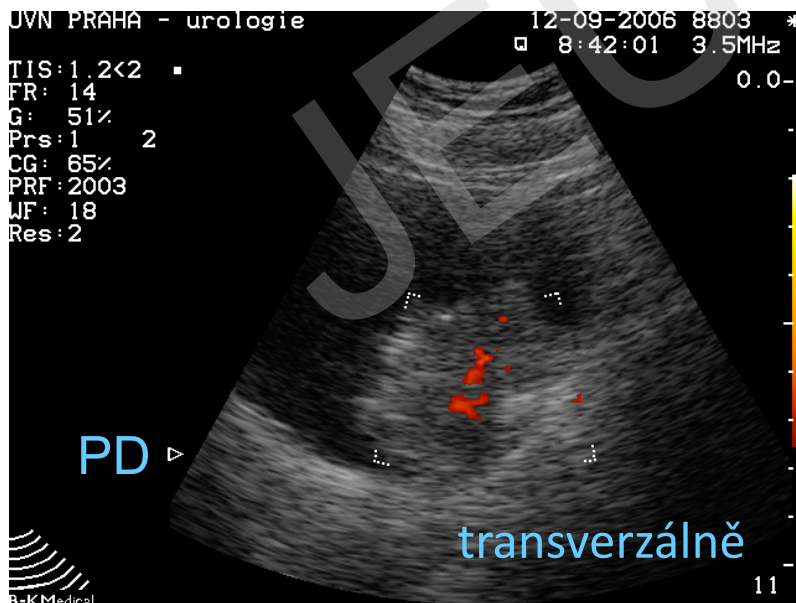


Dopplerovská ultrasonografie *nádor moč. měchýře*

transabdominálně

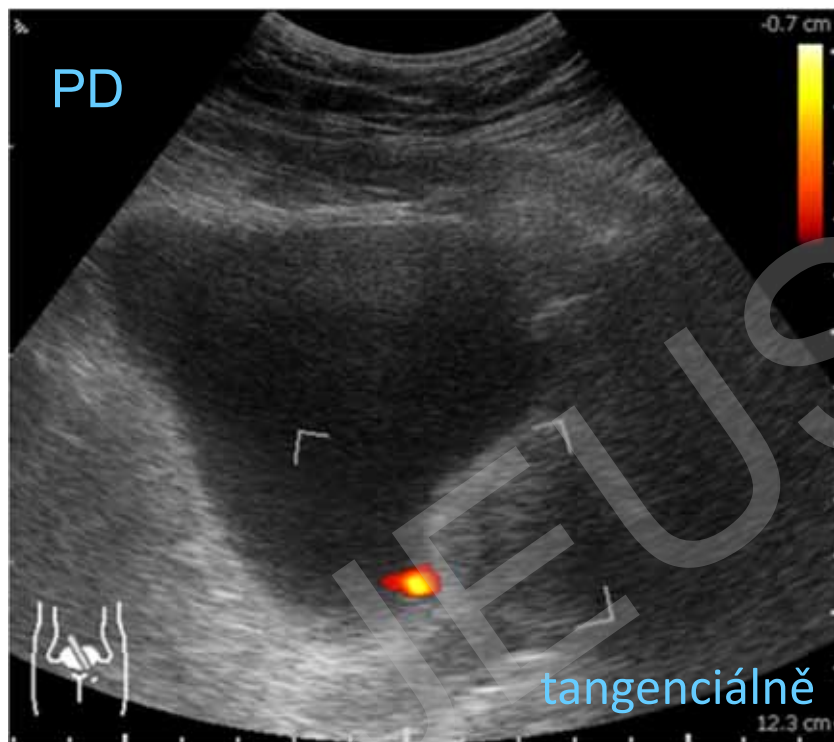


transrektálně

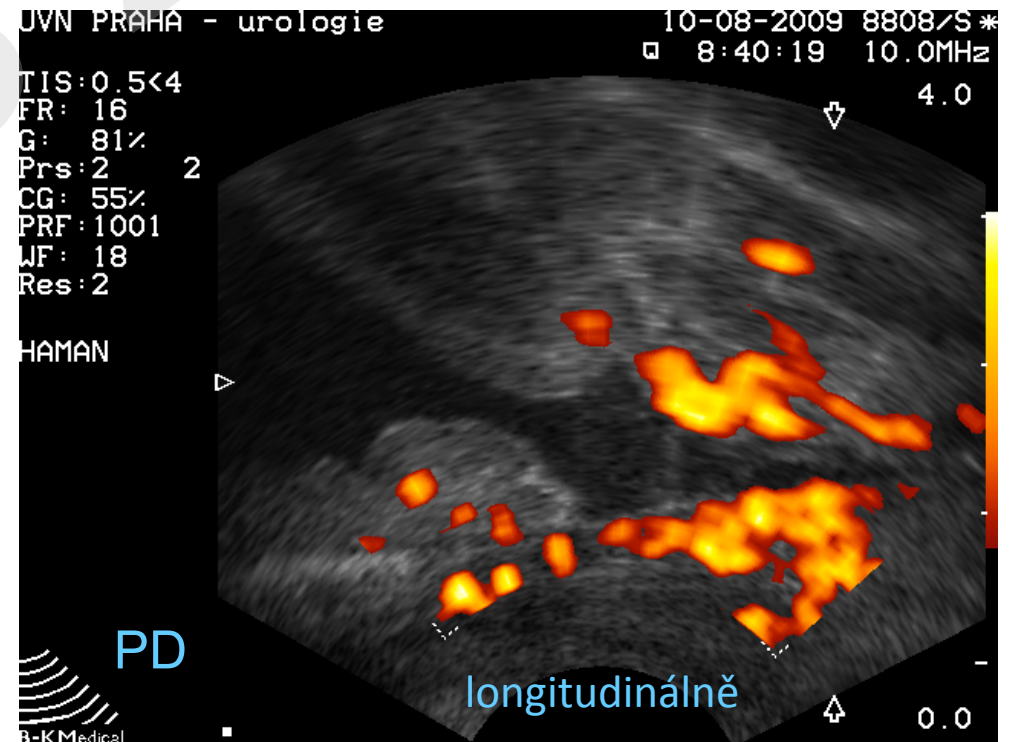


Dopplerovská ultrasonografie *prostata*

transabdominálně

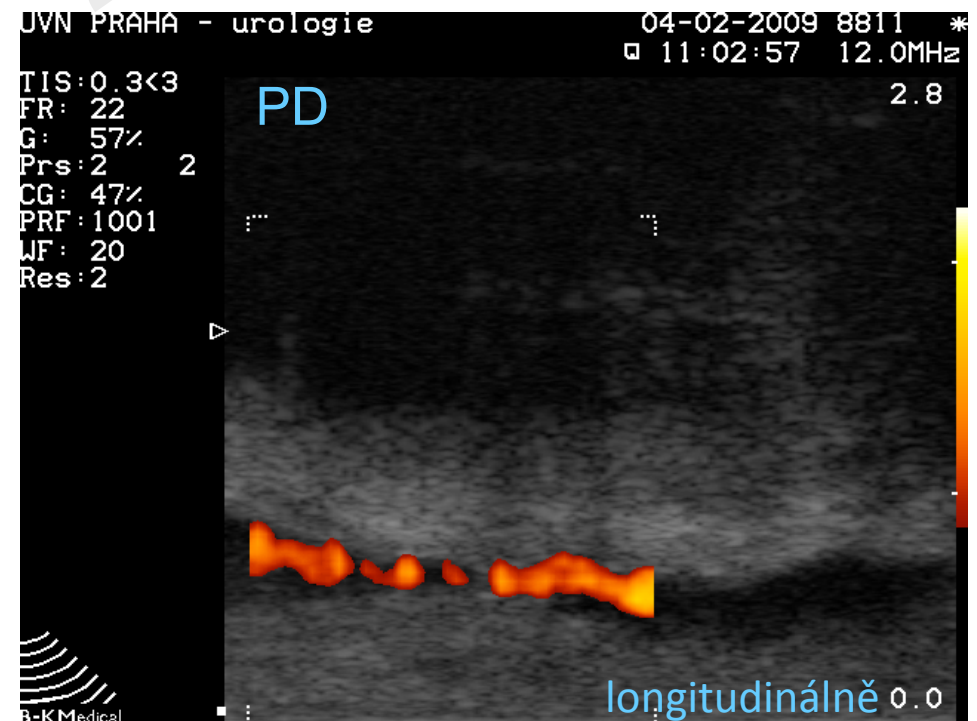
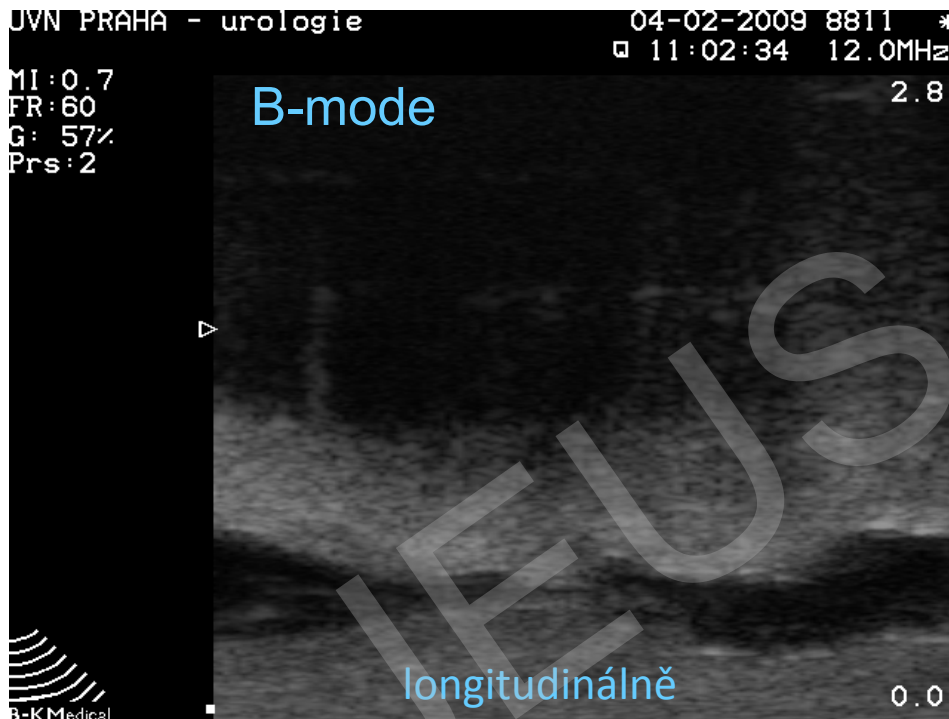


transrektálně

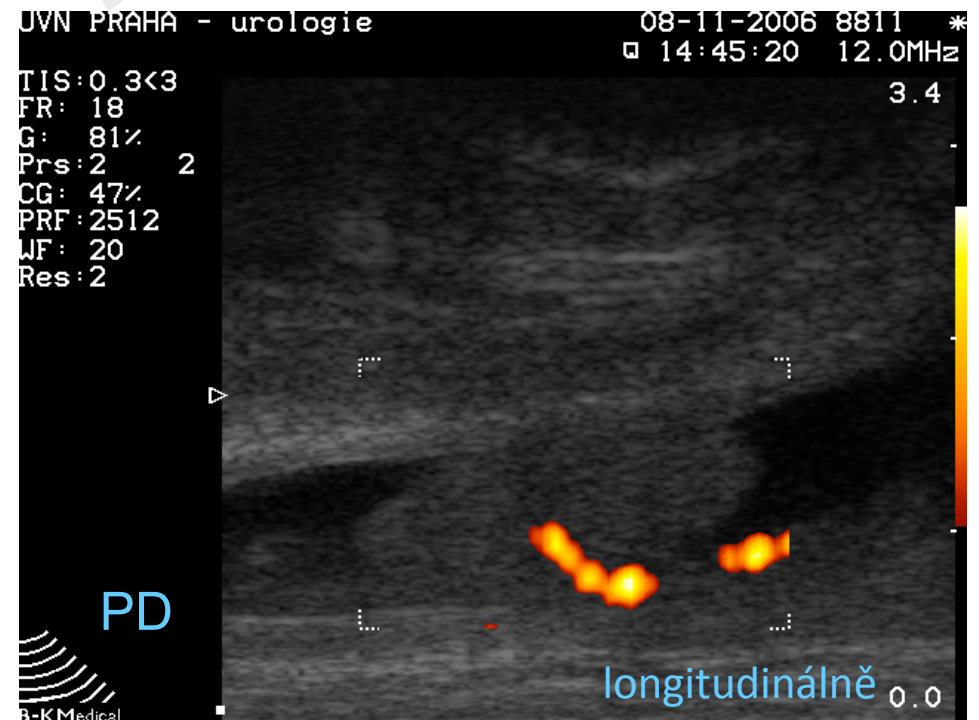
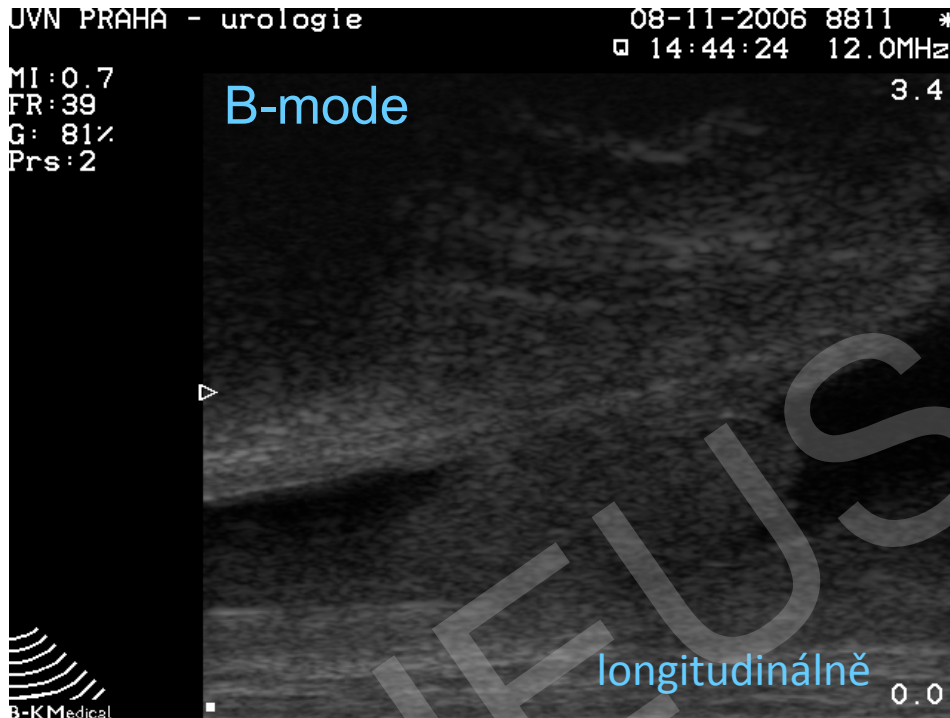


Dopplerovské vyšetření zevní genitál

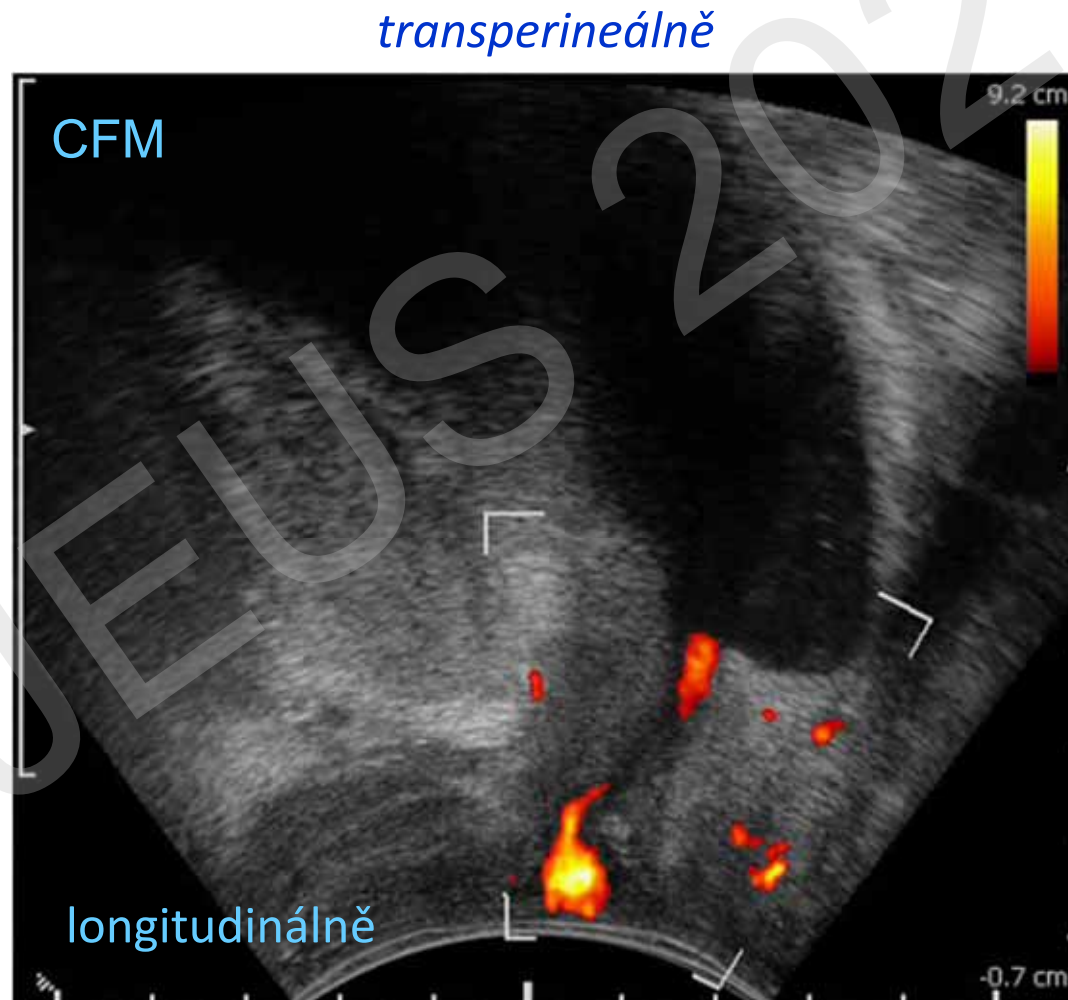
Dopplerovská ultrasonografie *striktura uretry*



Dopplerovská ultrasonografie *polyp uretry*

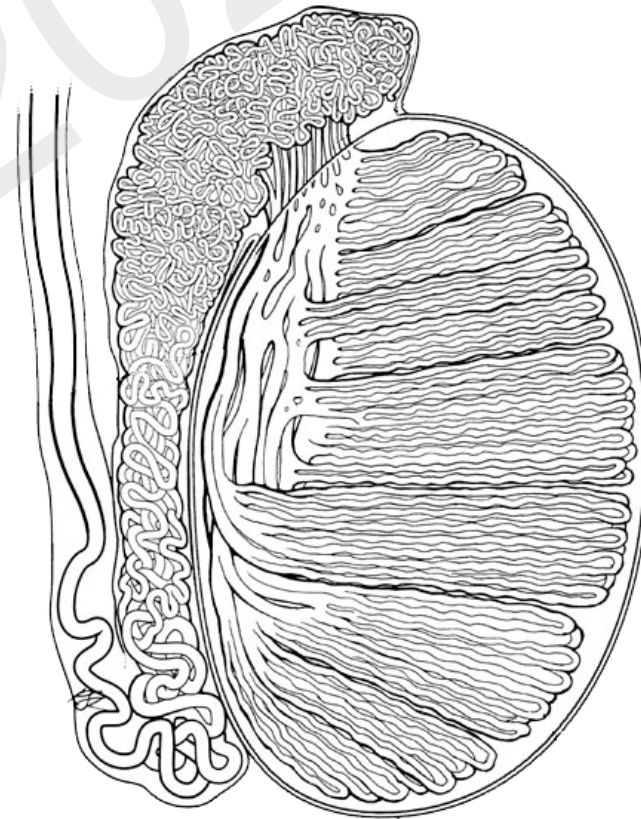
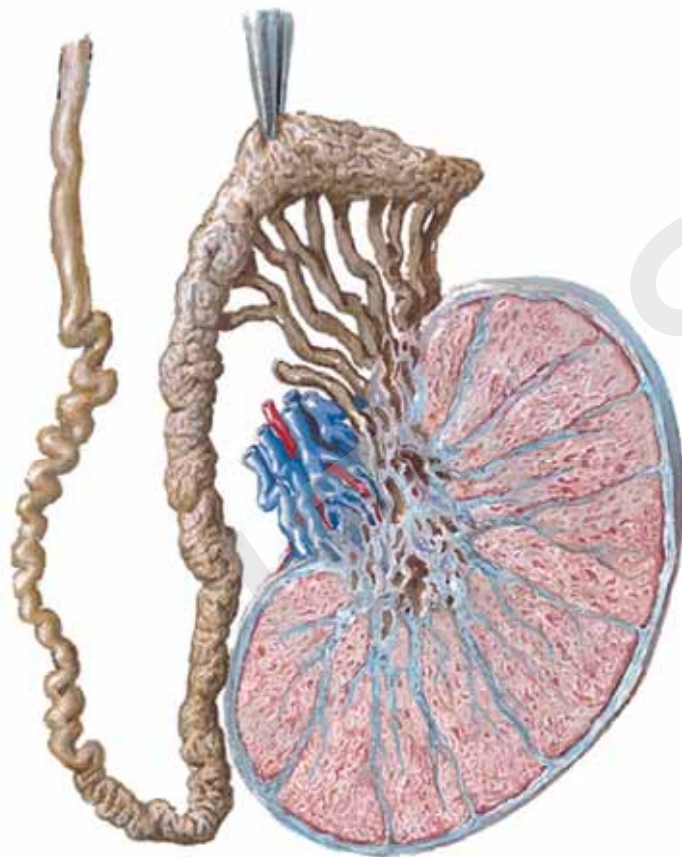


Dopplerovská ultrasonografie *inkontinence moče*



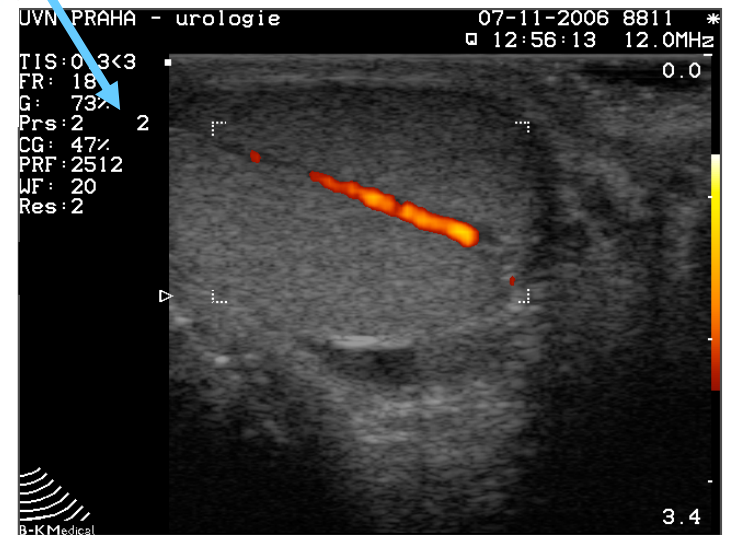
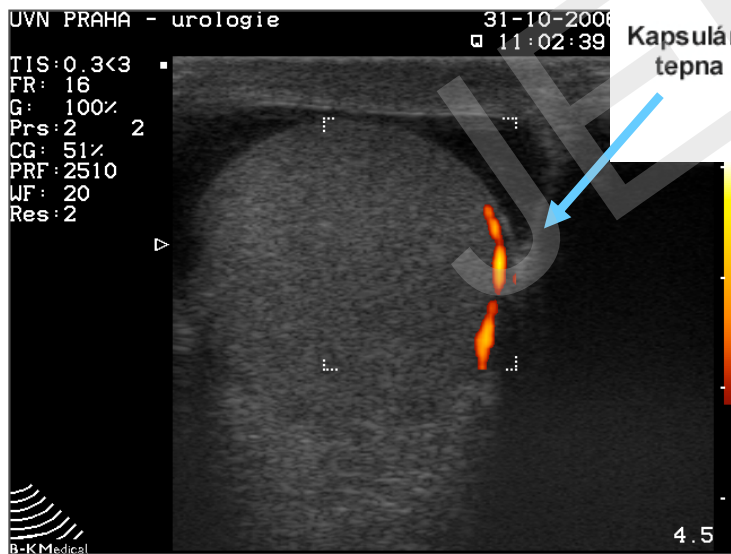
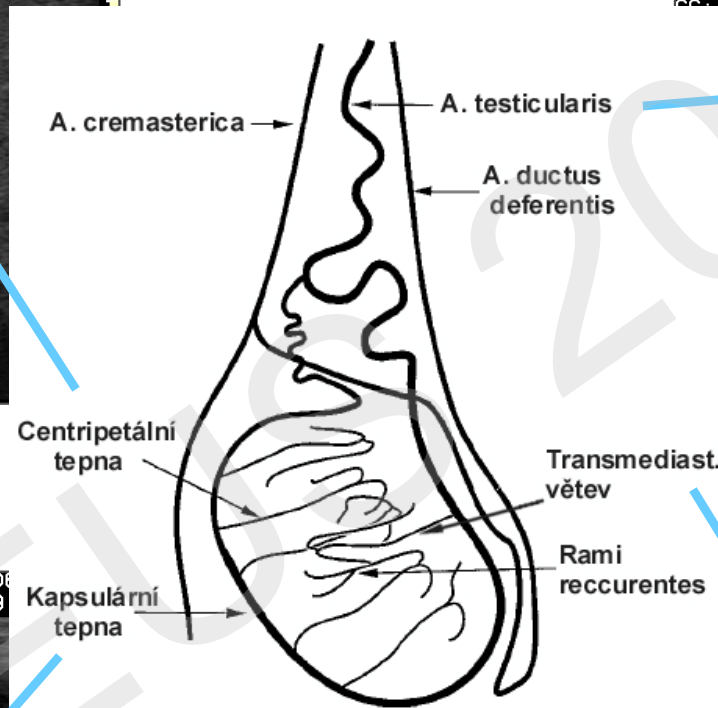
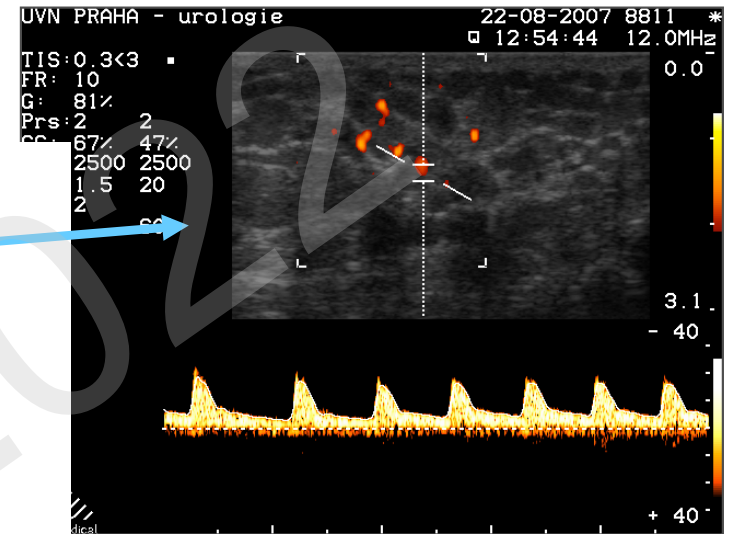
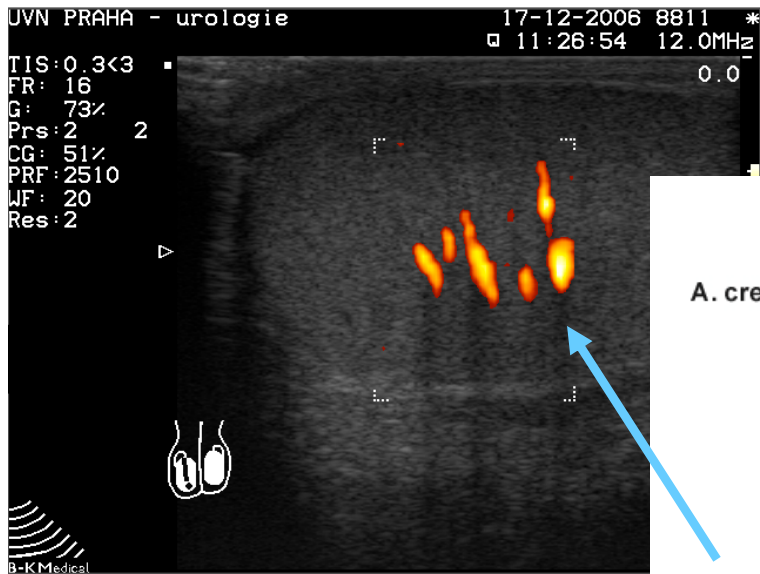
Dopplerovská ultrasonografie

obsah šourku



Dopplerovská ultrasonografie

šourek



Dopplerovská ultrasonografie

obsah šourku

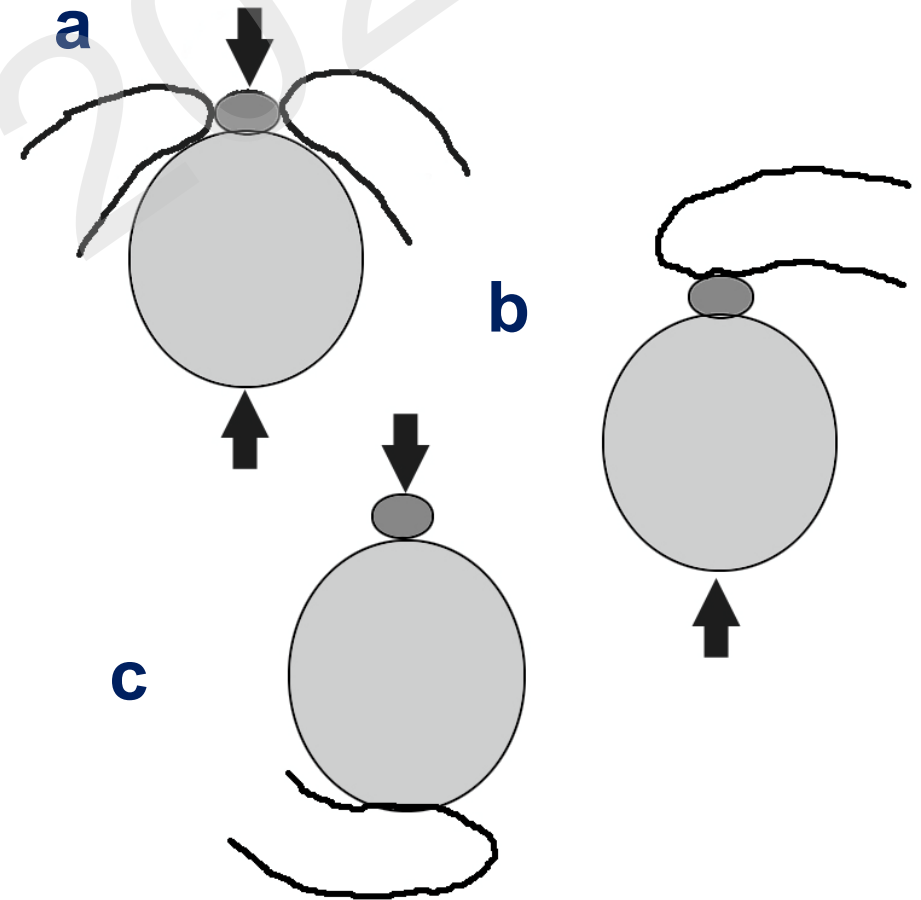
Možnost vyšetření z různých směrů!!!

- Ložisko

a) mezi prsty

b) prst na ložisku

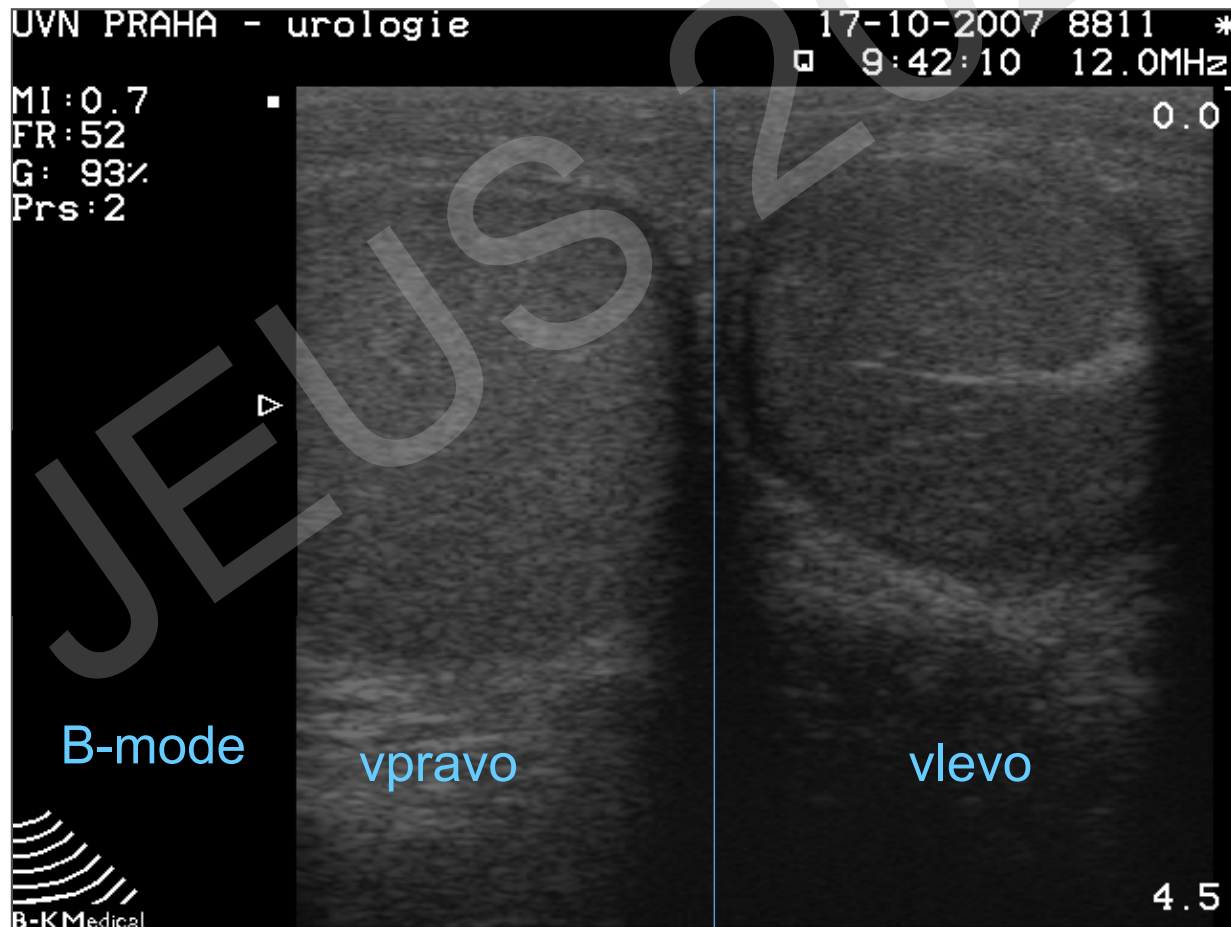
c) prst z druhé strany



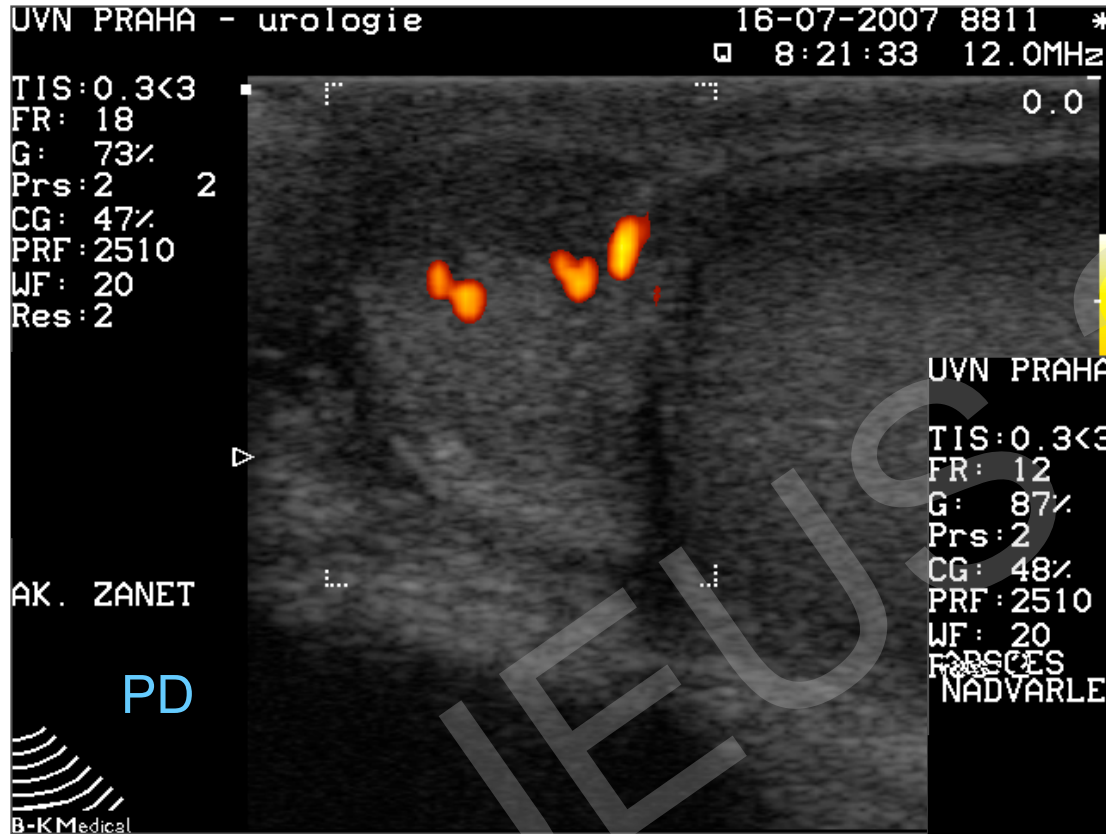
Dopplerovská ultrasonografie

obsah šourku

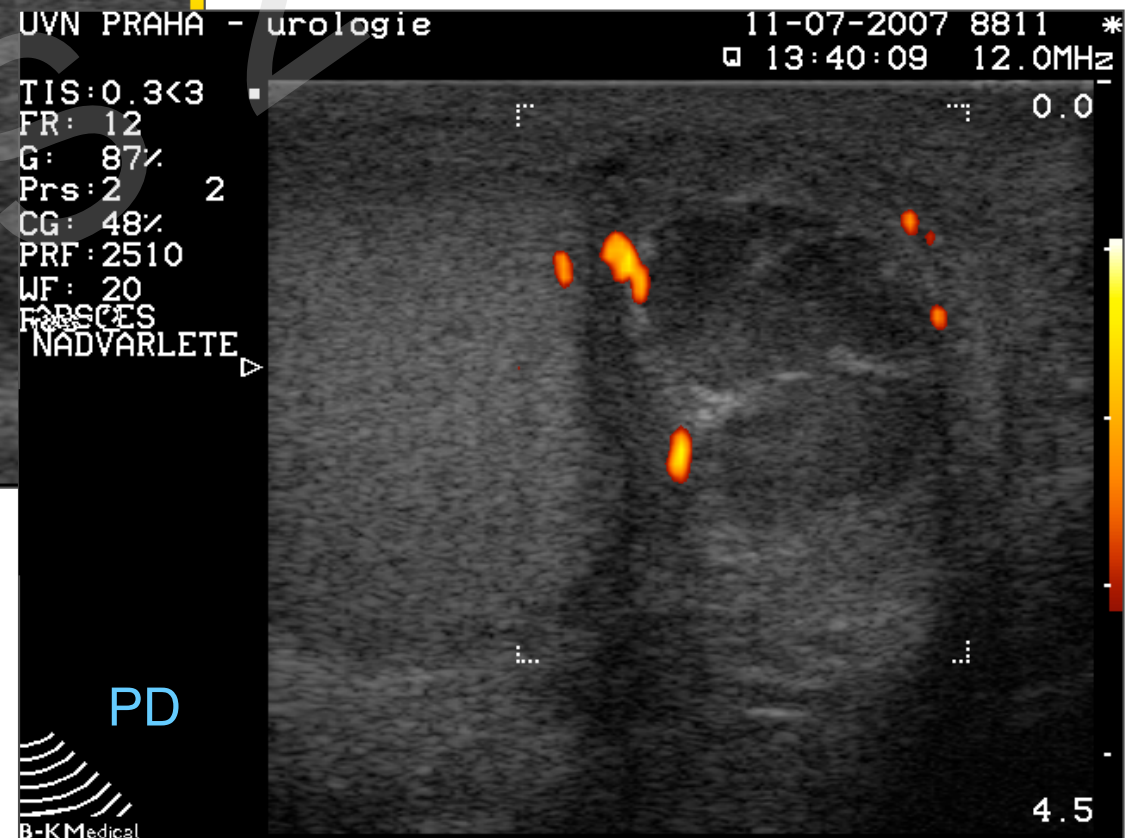Možnost vyšetření obou polovin najednou!!!



Dopplerovská ultrasonografie *epididymitída*

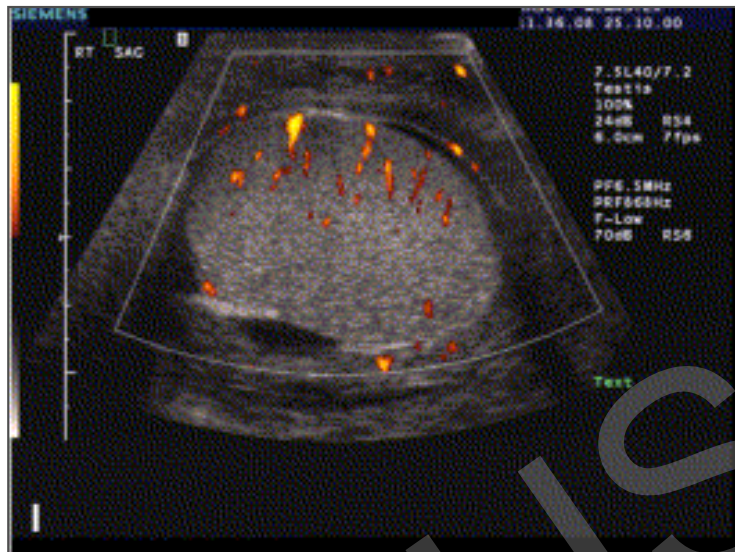


prostý záněť

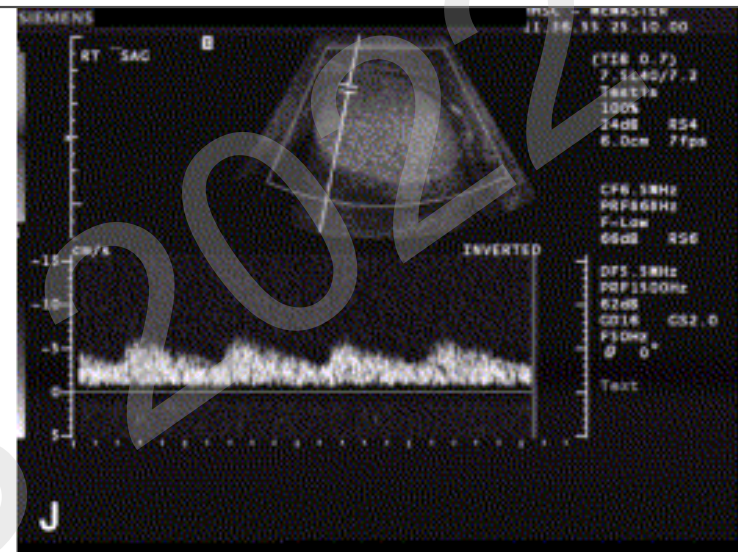


abscedující záněť

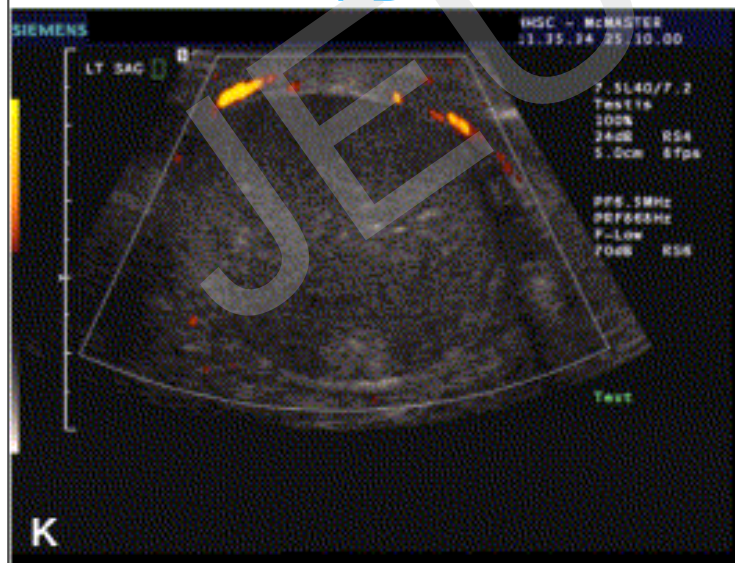Dopplerovská ultrasonografie torze varlete



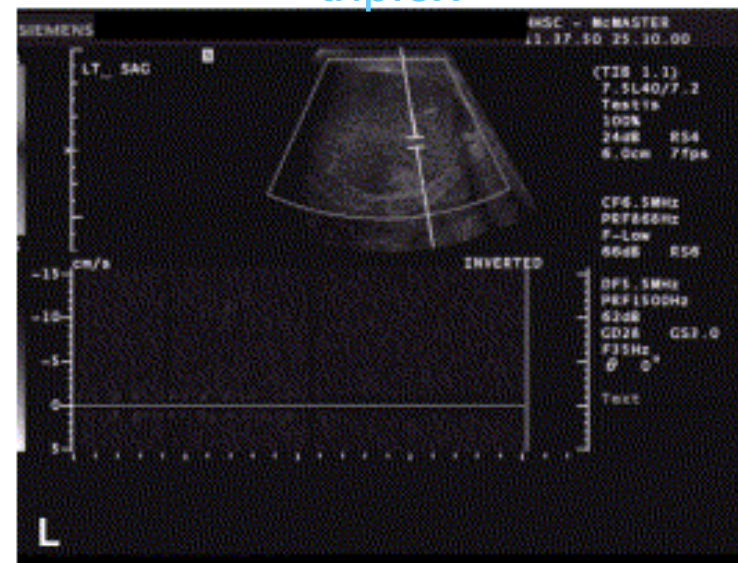
PD



triplex

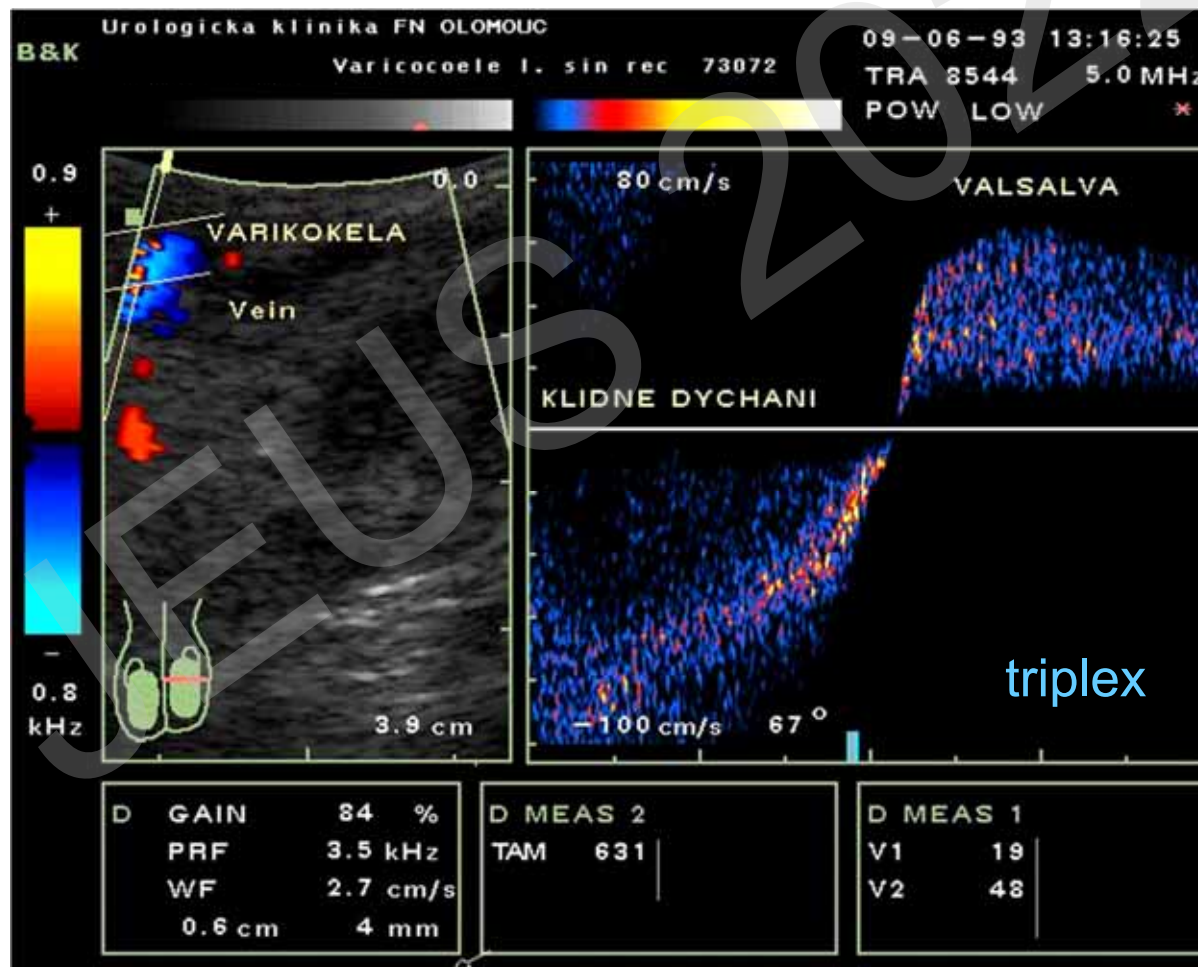


K

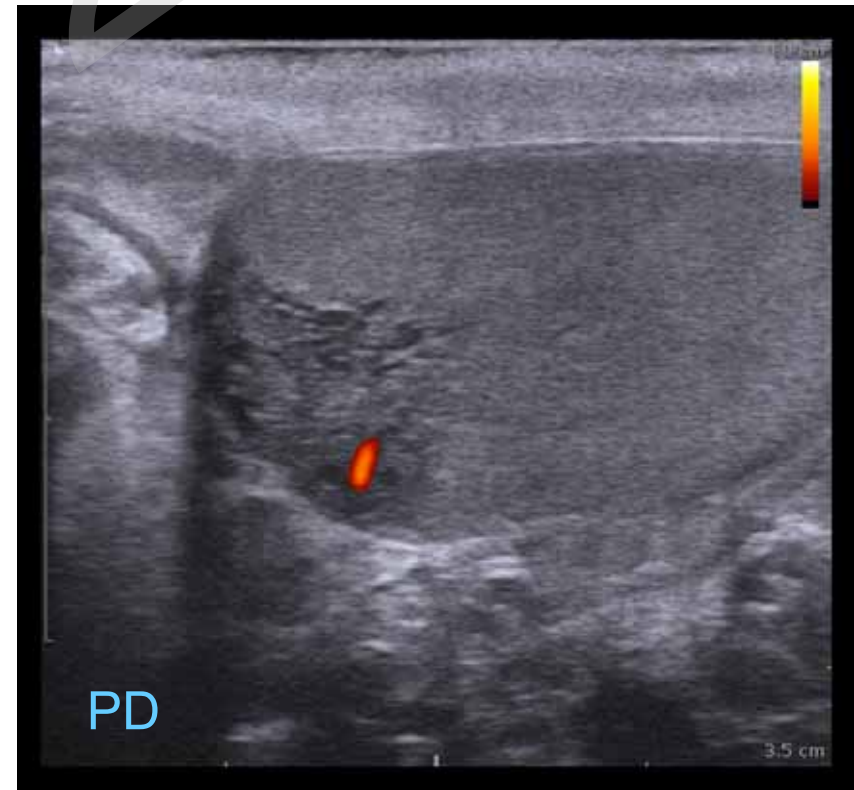
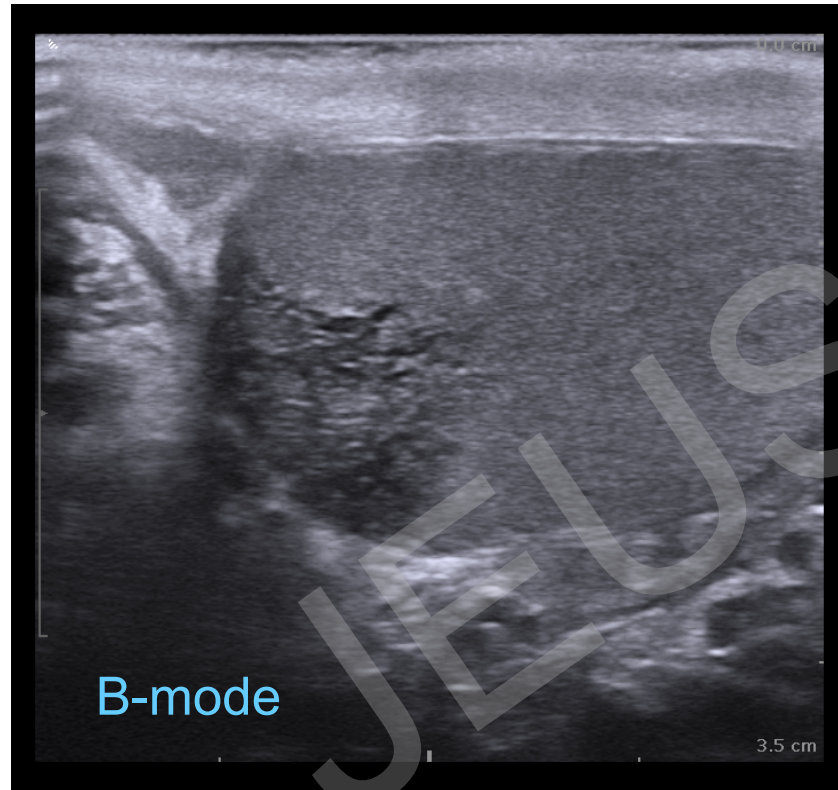


L

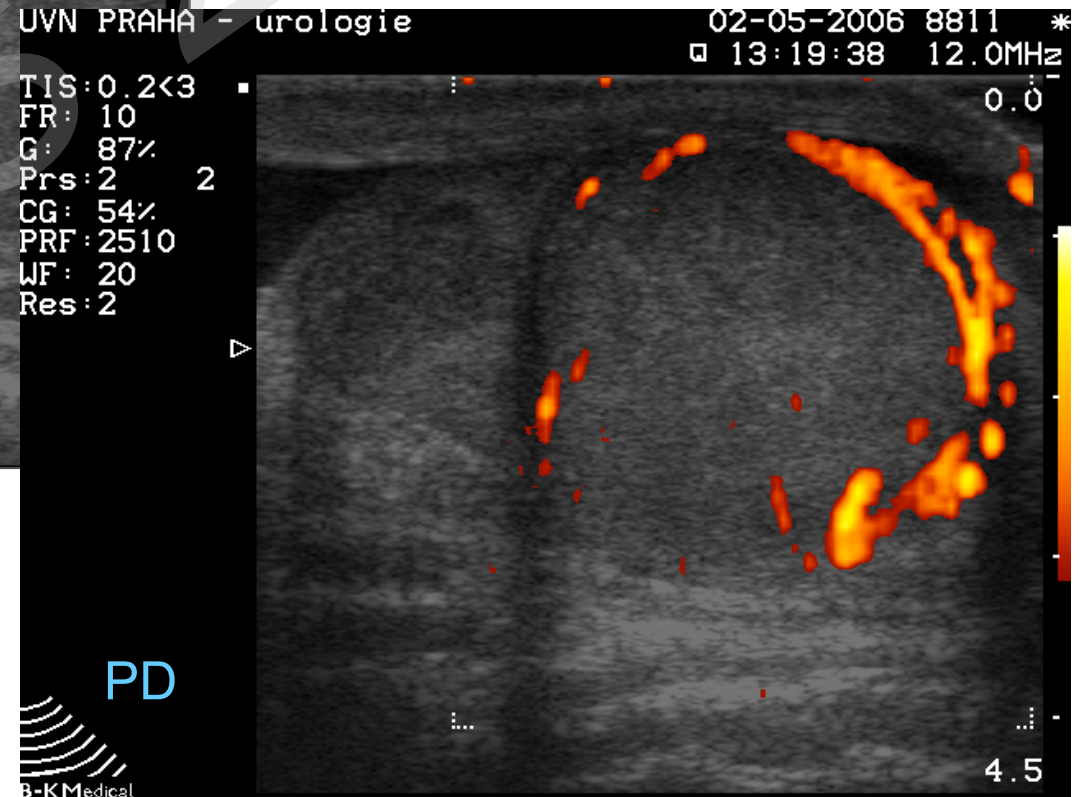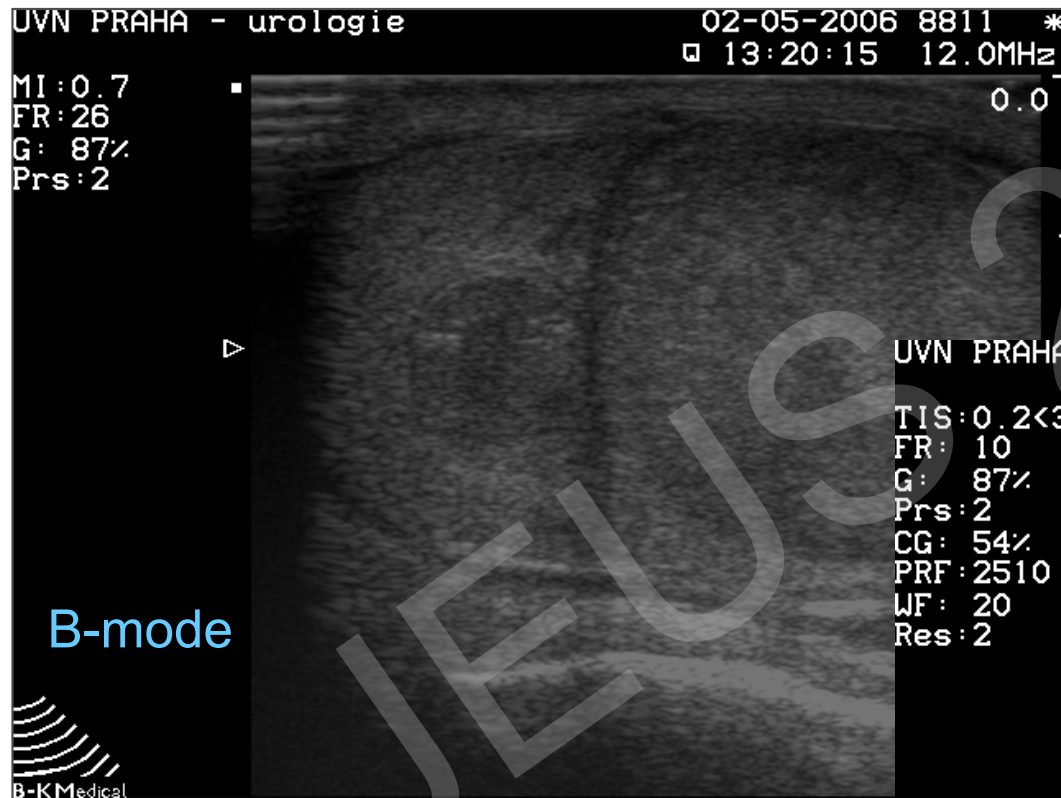
Dopplerovská ultrasonografie *varikokéla*



Dopplerovská ultrasonografie *varikokéla*

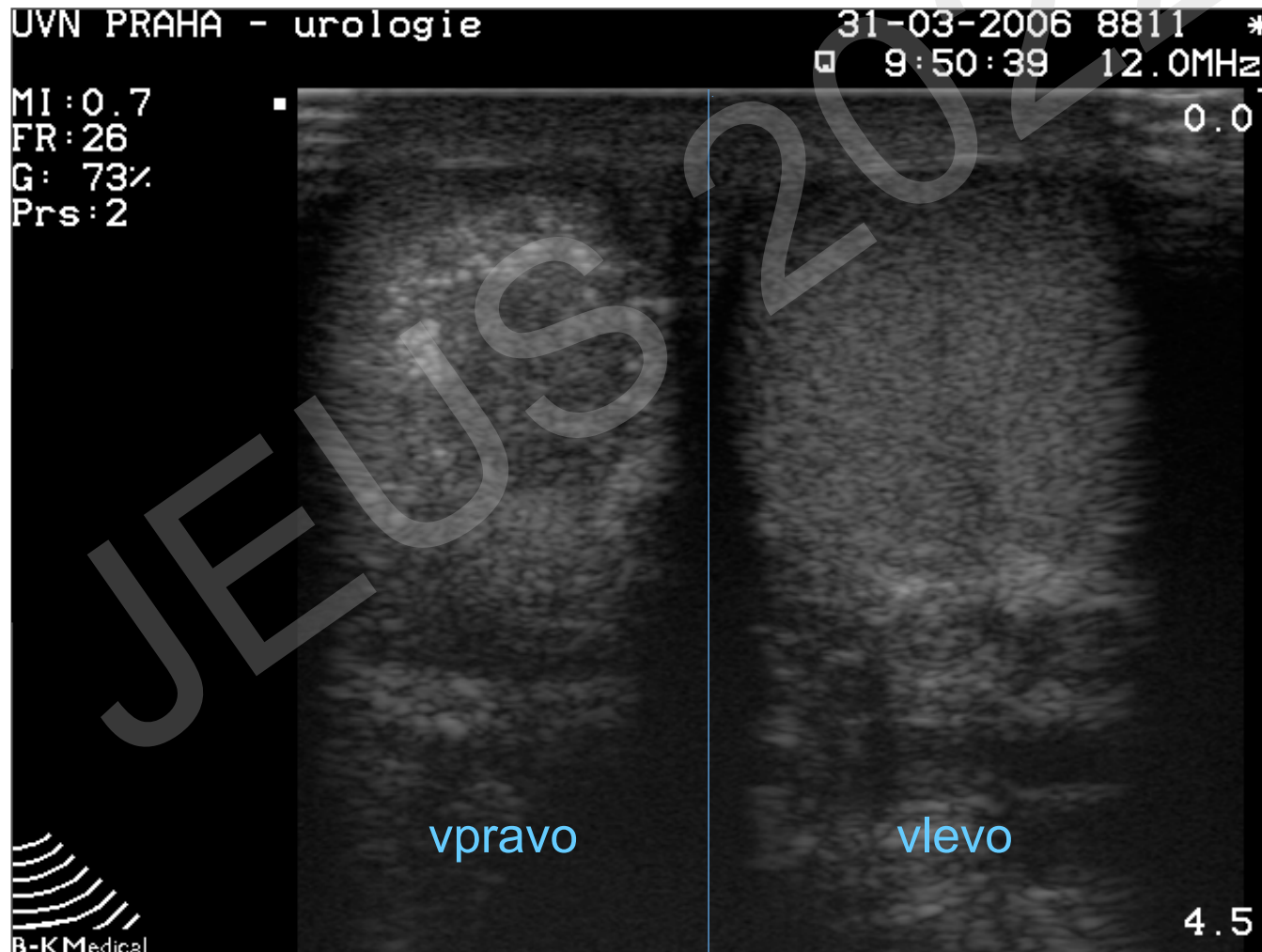


Dopplerovská ultrasonografie *nádor varlete*

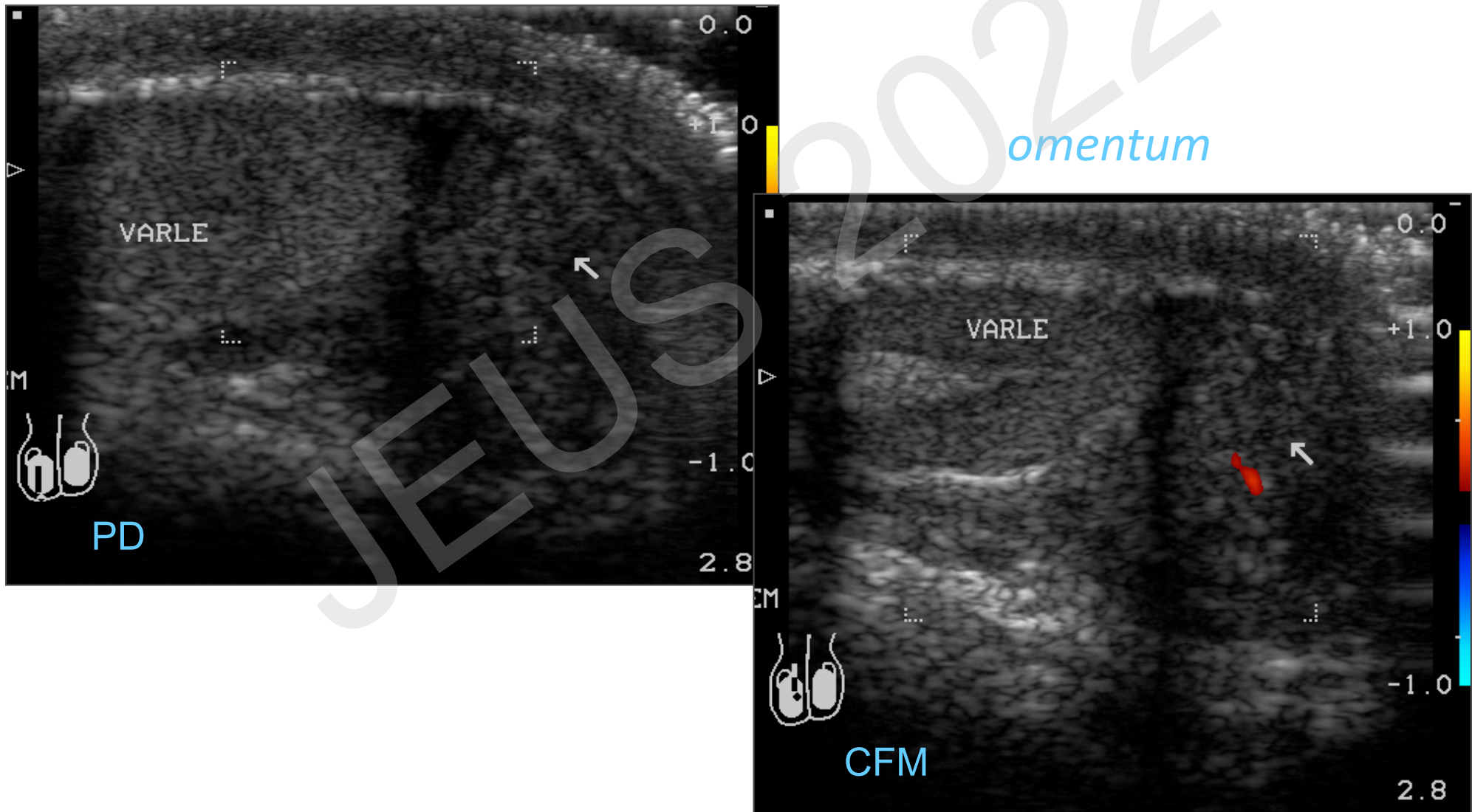


Dopplerovská ultrasonografie

nádor s mikrolitiázou



Dopplerovská ultrasonografie *herniace*



Dopplerovská ultrasonografie

cvičení

a. et v. renalis

a. testicularis, plexus pampiniformis

a. dorsalis penis, a. penis profunda